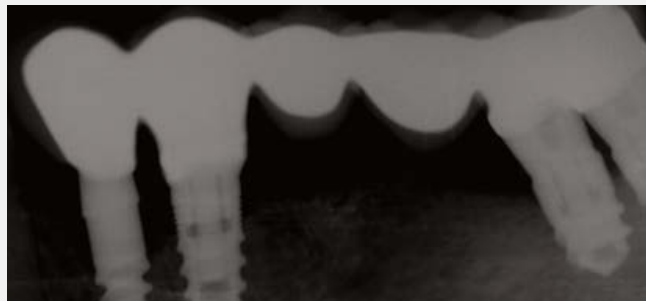

26

News No.26 January 2011

The Use Of 6mm Long
Implants In Cases With
Limited Bone Height:
A Preliminary 6-Month
Clinical Study



mis[®]
Make it Simple

The Use Of 6mm Long Implants In Cases With Limited Bone Height: A Preliminary 6-Month Clinical Study

Olimpiu L.Karancsi¹, Radu Sita¹, Emanuel A. Bratu¹

Background

Limited bone height restricts the use of standard length implants. Short implants may be used in these cases as an alternative for lengthy and expensive augmentation procedures. Recent clinical studies indicate that short implants may support prosthetic restorations quite adequately, but still clinical

documentation is sparse. The purpose of this study was to evaluate the clinical behavior of short implants in reduced bone conditions. The hypothesis was: "Short implants in atrophied jaws are able to result in similar long-term survival rates compared with standard implants.

Materials And Method

Study was approved by IRB (Helsinki).

Subjects - Twenty three implants were placed in 11 patients in different clinical situations. All patients were healthy and with good oral hygiene, but smoking was not an exclusion criterion. Twenty three 6mm implants (Seven, MIS Implants, Bar-Lev, Israel) diameter 4, 2mm,

¹Department of Implant restorations University of Medicine and Pharmacy Timisoara Romania

Clinical case presentation: **Case 1**

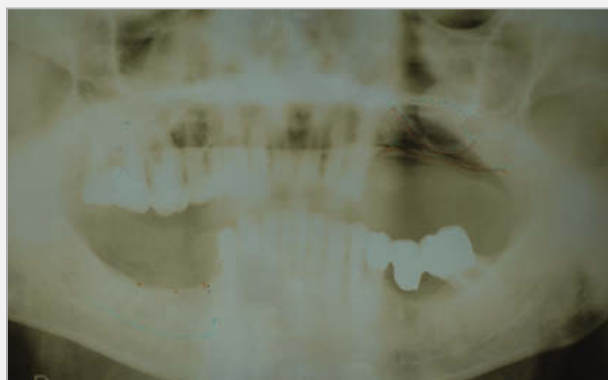

Fig. 1 Case 1 - Preoperative x-ray. Note the reduced bone height above the mental foramen.

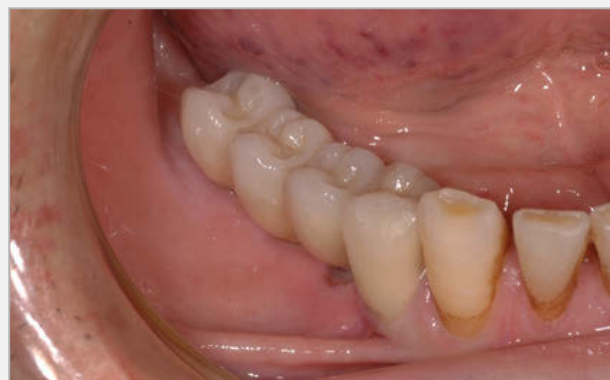

Fig. 3 Case 1 - Final restoration in position.

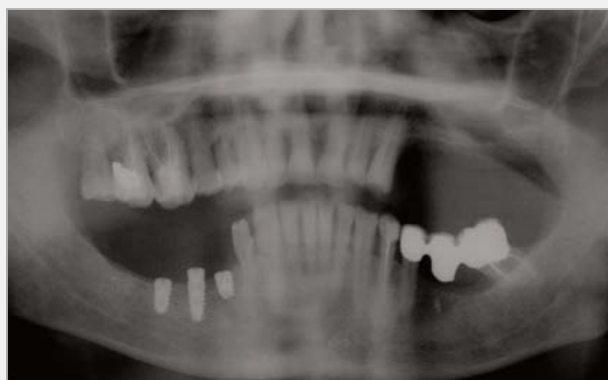

Fig. 2 Case 1 - Postoperative x-ray with the 4.2 6mm Seven implant in position.

5 mm and 6 mm were used. The selected sites were wide alveolar ridges (>6mm) and less than 8 mm of bone height. None of the implants required bone augmentation.

Surgical procedure - The implants were inserted according to the manufacturer protocol. A crystal incision was performed and full mucoperiosteal flaps were elevated in the areas of implant insertion. Bone was cleaned of periosteal tissue and markings of implant position with a round bur were performed. Then 2 mm pilot drill marked the depth and angulation of the implant. Final drilling diameter and depth were achieved with the drill provided with each implant. Implants were inserted using the hand piece or ratchet, until final position was reached, the threads being completely covered by bone. In the maxilla, the final drill was used only in the cortical bone. All the implants were covered with flaps and healing was subgingival.

Medication included antibiotics (Augmentin, 1gr Smithkline Beecham) for 6 days and analgesics (Ketonal forte 200mg) for 3 days.

None of the implants were immediately loaded. Loading was done 3 months after insertion for the mandibular implants and 6 months after insertion for the maxillary implants. The implants were followed-up for 6 months after loading. All of the loaded implants were splinted with fixed partial dentures either among themselves or to standard sized implants. Periotest and Ostell measurements were taken on insertion and at uncover. After 3 months of subgingival healing the mandible and 6 months of subgingival healing in the maxilla, implants were uncovered and loaded with fixed partial dentures. All 6 mm implants inserted were splinted to neighboring standard implants or to each other. None of the 6 mm implants was left stand alone. Follow-up was done 6 months after loading. Bone loss measurements and probing depths measurements were done on the distal side of all 6 mm implants.

Results

All implants showed good primary stability at placement. No implant was lost during healing period. Prior to loading, all implanted had negative periotest results. None of the tested implants was lost after 6 months of loading. In addition, bone loss as measured on panoramic x-ray was no more than 1 mm and probing depths were no more than 5mm. However, patients with thick peri-implant tissue presented smaller probing depths comparing to the ones with thin soft tissue.

Conclusion

Within the limitations of this preliminary study, it can be concluded that short implants are a viable treatment option when splinted, at least for 6 months after loading. Short implants seem to be the optimal option as supplementary implants in free end situations, especially in the rear mandible areas, when combined with standard implants. Although there are several studies which suggest that short implants are a viable solution for the use

Clinical case presentation: **Case 2**

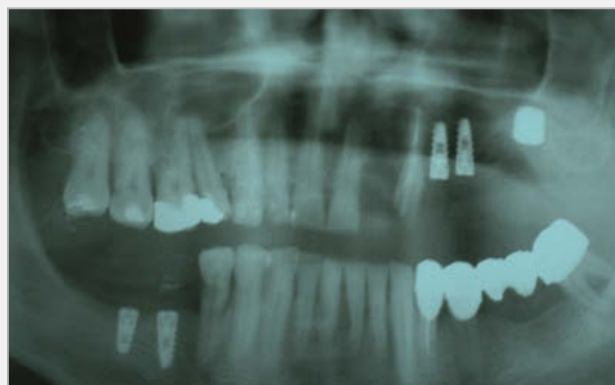

Fig. 4 Case 2 - Postoperative x-ray with the 6mm length and 6mm diameter Bio-com implant. The patient refused the classic external sinus elevation procedure.

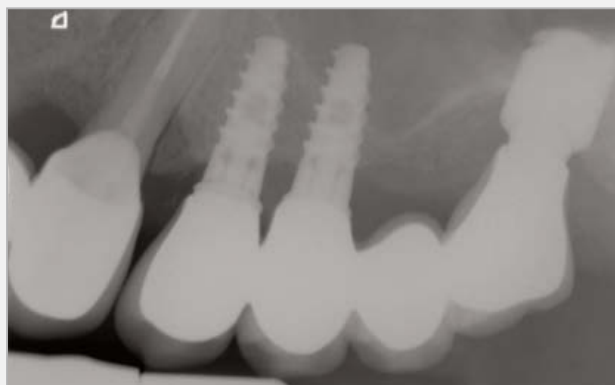


Fig. 6 Case 2 - X-ray at 6 months with final restoration in place.

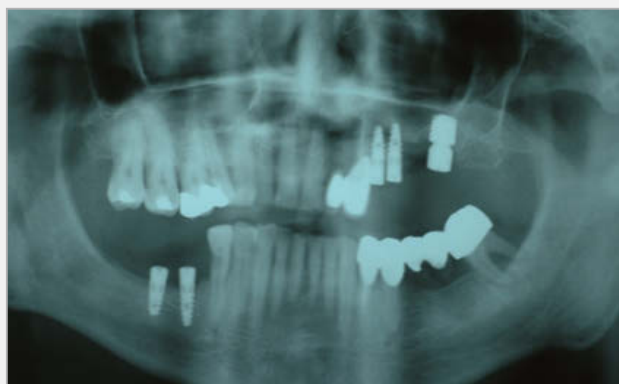

Fig. 5 Case 2 - X-ray after uncover of the implant with healing screw in position.

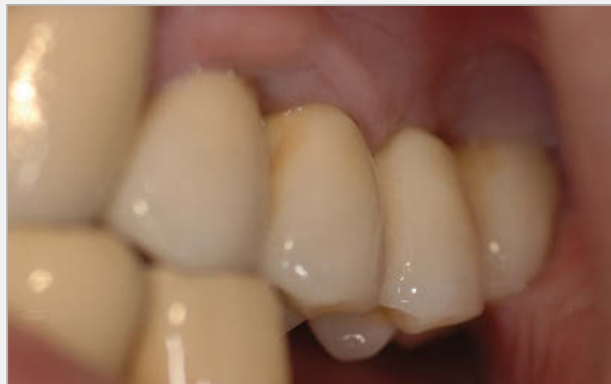

Fig. 7 Case 2 - Intraoral view of the restoration.

as stand-alone implants, there are sufficient arguments in favor of implant mechanical overload. Further investigation is needed in order to come up with more clear statements. At this point in time and although the clinical results of these short implants were favorable, it is recommended that short implants are used in combination with longer implants, especially when used in type III or IV bone that is often found in the maxilla. Bone remodeling may be due to a higher insertion torque caused by the large diameter of the implant and higher surface contact between implant and cortical bone.

References

1. Short implants—an analysis of longitudinal studies F. das Neves, D. Fones, S. Bernardes, C. do Prado, A. Neto The Journal of Prosthetic Dentistry, Volume 96, Issue 4, Pages 288-288
2. Finite element stress analysis of the effect of short implant usage in place of cantilever extensions in mandibular posterior edentulism Akca K; Iplikcioglu H. Journal of oral rehabilitation 2002, vol.29, no4, pp.350-356
3. Short Dental Implants: A Literature Review and Rationale for Use Carl E. Misch Issue Date: August 2005, Posted On: 8/5/2005 www.dentistrytoday.com.
4. Long-term follow-up of severely atrophic edentulous mandibles reconstructed with short Brånemark implants. Friberg B, Grondahl K, Lekholm U, Brånemark PI. Clin Implant Dent Relat Res. 2000; 2:184-189.
5. Short (6-mm) nonsubmerged dental implants: results of a Multicenter clinical trial of 1 to 7 years. Bruggenkate CM, Asikainen P, Foltzik C, et al. Int J Oral Maxillofac Implants. 1998; 13:791-798.
6. Dental implants of reduced length: a literature review and clinical report of Biohorizons dental implants. Misch CE, Steigenga J, Kazor C Implant Dent. In press (2006).
7. Short Implants Placed One-Stage in Maxillae and Mandibles: A Retrospective Clinical Study with 1 to 9 Years of Follow-Up Paulo Maló, Miguel de Araújo Nobre, Bo Rangert, Clinical Implant Dentistry and Related Research, Volume 9 Issue 1, Pages 15 – 21; Published Online: 16 Feb 2007
8. Performance of Short Implants in Partial Restorations: 3-Year Follow-up of Osseotite(R) Implants Goené Ronnie, Bianchesi Carlo, Hüerzeler Markus, Del Lupo Ricardo, Testori Tiziano, Davarpanah Mithradade, Jalbout Ziad Implant Dentistry: September 2005 - Volume 14 - Issue 3 - pp 274-280
9. Short implants in maxillae and mandibles: a retrospective study with 1 to 8 years of follow up Anita Eduardo, Orive Gorka Journal of Periodontology , Posted online on 16 February 2010. (doi:10.1902/jop.2010.090637)
10. Use of short implants for functional restoration of the mandible after giant cell tumor removal. Case report. Cozzolino A, Balleri P, Ruggiero G, Veltri M Minerva Stomatol. 2006 May; 55(5):307-14
11. Factors affecting late implant bone loss. A retrospective analysis Chung, Tae-ju Oh, Lee, Misch, Wang. JOMI, 2007, VOL 22

Clinical case presentation: **Case 3**

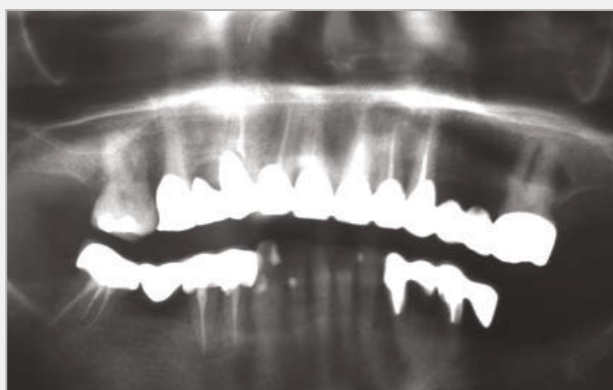

Fig. 8 Case 3 - Panoramic x-ray with the initial status.

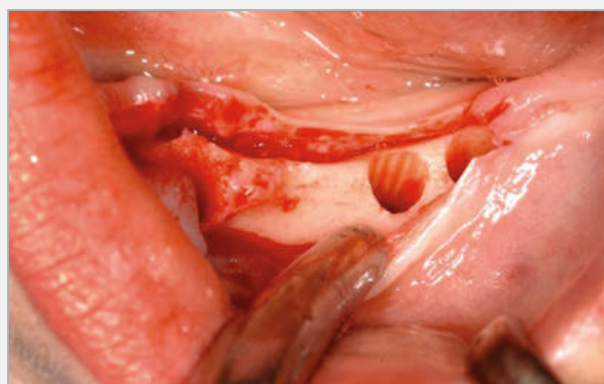


Fig. 10 Case 3 - intraoral appearance after drilling.

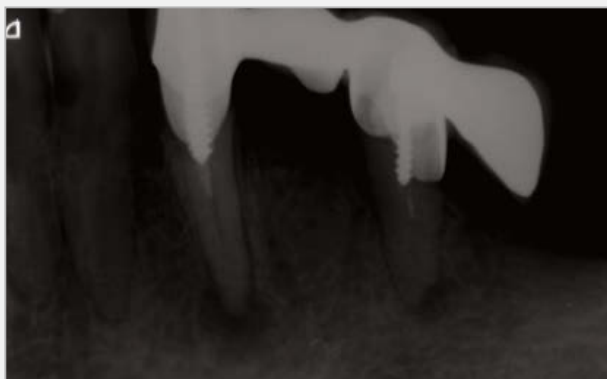


Fig. 9 Case 3 - Intraoral x-ray before implant placement.

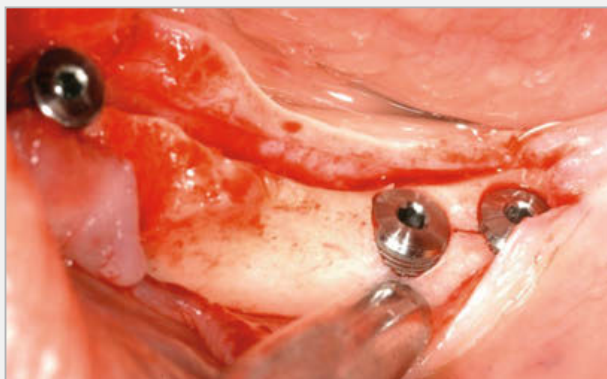


Fig. 11 Case 3 - implants in place.

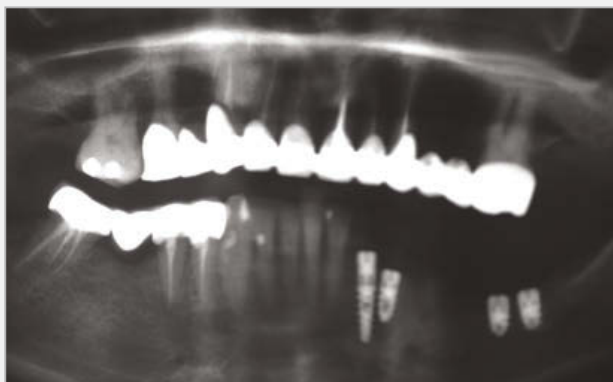


Fig. 12 Case 3 - Panoramic x-ray after insertion.

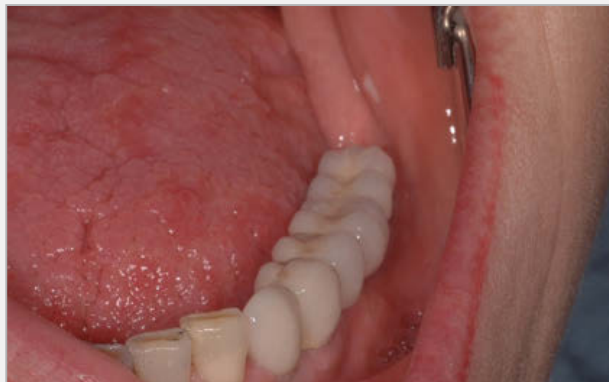

Fig. 15 Case 3

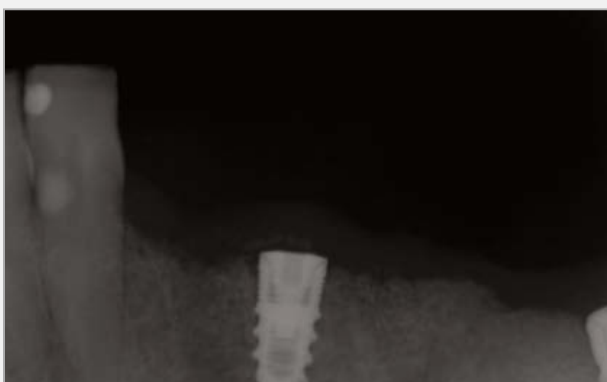

Fig. 13 Case 3 - The implant in position 3,3 was lost because of residual infection and replaced by a 3mm I 13mm UNO implant after 2 months. During this period the other implants recieved a resin provisional restauration. 2X 4,2mm L6.




Fig. 16 Case 3 - Intraoral x-ray at 6 months after bridge fixation. See the direction of the mandibular nerve.

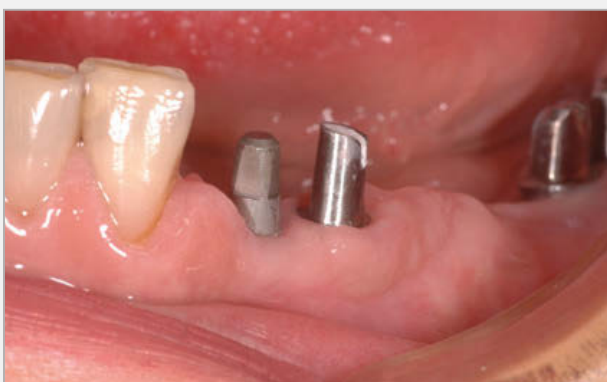

Fig. 14 Case 3

MIS's Quality System complies with international quality control standards: ISO 13485:2003 - Quality Management System for Medical Devices, ISO 9001: 2008 - Quality Management System and CE Directive for Medical Devices 93/42/EEC. MIS's products are cleared for marketing in the USA and CE approved.

© MIS Corporation. All rights Reserved



MIS Implants Technologies Ltd.
www.mis-implants.com