



Our Research is Your Success...

Published online:
January
2016

CLINICAL ORAL IMPLANTS RESEARCH

”

Esthetic Assessment of Immediately Restored Implants Combined with GBR and Free Connective Tissue Graft”

Roni Kolerman; Joseph Nissan; Eitan Mijiritsky;
Nasreen Hamoudi; Carlo Mangano; Haim Tal;

* Roni Kolerman, Joseph Nissan, Eitan Mijiritsky, Nasreen Hamoudi, Carlo Mangano, Haim Tal.
Clinical Oral Implants Research, November 2016, John Wiley & Sons Ltd.
DOI: 10.1111/CLR.12755



¹ Roni Kolerman
² Joseph Nissan
² Eitan Mijiritsky
³ Nasreen Hamoudi
⁴ Carlo Mangano
¹ Haim Tal

“Esthetic Assessment of Immediately Restored Implants Combined with GBR and Free Connective Tissue Graft”

SUMMARY.

Aim

Esthetic assessment of immediately restored implants combined with GBR and free connective tissue (CT) graft.

Methods

Case-control, retrospective study involving 34 patients treated with maxillary anterior single implants (SEVEN®, MIS Implants Technologies LTD.), immediately placed and restored. Clinical and esthetic results were analyzed using standard clinical examination and a comprehensive index, comprising pink esthetic and white esthetic scores (PES/WES). The height of the implant crown and the corresponding height of the contralateral tooth crown were measured to identify mucosal recessions. The distance from the mucosal margin to the implant shoulder (DIM) was measured on the master model.

Results

Thirty of 34 implants fulfilled the strict success criteria set for dental implants with regard to osseointegration. Success was defined as implants with bone loss not exceeding 1.5 mm during the first year and losing not more than 0.2 mm for each successive year. The other four implants were stable but did not meet the bone loss criteria mentioned above and defined as survived implants. Mean PES / WES was 14.44 ± 2.34 (range: 9–20). Mean PES was 7.12 ± 1.89 (range: 1–10). The highest mean values were achieved for the variable of root convexity / soft tissue color and texture (1.71 ± 0.46) whereas the mesial papilla (1.09 ± 0.62) proved to be the least pleasing. The mean WES was 7.32 ± 1.25 (range: 5–10). The difference between IC and contralateral TC was 0.54 mm. The mean value for the facial DIM was 3.82 ± 0.87 mm.

Conclusions

An evaluation of soft and hard tissue augmentation in immediately restored immediate implant procedures was employed to obtain stable hard and soft tissues. The combined GBR and CT graft procedure achieved favorable peri-implant soft tissue condition and esthetic results. However, recession and incomplete papillas were frequently observed.

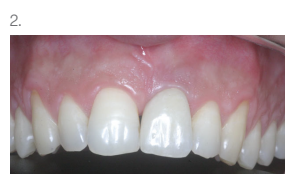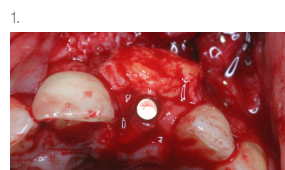


Fig.1. Free connective tissue graft placed over Type 1 collagen membrane and allograft.

Fig.2. Final zirconia crown at 1 year (PES-WES score 20).

Authors' affiliations

¹ Department of Periodontology and Dental Implantology, The Maurice and Gabriela Goldschleger School of Dental Medicine, Tel Aviv University, Tel Aviv, Israel

² Department of Oral Rehabilitation, The Maurice and Gabriela Goldschleger School of Dental Medicine, Tel Aviv University, Tel Aviv, Israel

³ General Practitioner, Private Practice, Calanswa, Israel

⁴ Dental School, University of Varese, Varese, Italy