



Our Research is Your Success...

This study was  
not sponsored  
by MIS!

January  
2012

Published in:

JOMI

”

## Clinical and Radiological Evaluation of 70 Immediately Loaded Single Implants in the Maxillary Esthetic Zone: Preliminary Results After 1 Year of Functional Loading”

Luca Di Alberti, DDS, PhD , Federica Donnini , RDH, Claudio Di  
Alberti, DDS, MSc, Michele Camerino, DDS, Nicole Sgaramella,  
MD, DDS, Lorenzo Lo Muzio, MD, DDS, PhD

\* INT J Oral Maxillofac Implants 2012, 27:181-186



<sup>1</sup> Luca Di Alberti  
 Federica Donnini  
 Claudio Di Alberti  
 Michele Camerino  
<sup>2</sup> Nicole Sgaramella  
<sup>3</sup> Lorenzo Lo Muzio

## "Clinical and Radiological Evaluation of 70 Immediately Loaded Single Implants in the Maxillary Esthetic Zone: Preliminary Results After 1 Year of Functional Loading"

### ABSTRACT.

#### Objectives

A key challenge in implant treatment in the esthetic zone is to provide patients with crowns and peri-implant mucosa that are in harmony with the adjacent teeth to restore both function and esthetics. The aim of the present study was to show the preliminary results of the immediate loading protocol in the maxillary esthetic zone that is designed to preserve the soft tissue.

#### Materials and Methods

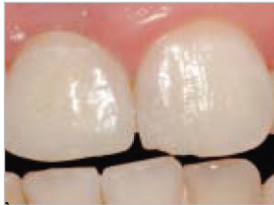Patients were treated with immediately loaded single-tooth implants (Seven, MIS). Implants were inserted in fresh postextraction sites with clinically and radiologically healed bone. After 8 weeks of loading, the provisional crowns and abutments were modified as needed to enhance the esthetics of the gingival margins. Definitive restorations were delivered 4 to 6 months postoperatively.

#### Results

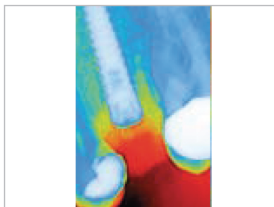
Seventy patients were treated: 25 implants were placed in fresh extraction sites, and the remaining 45 implants were inserted in healed single edentulous sites. All implants were stable, and radiographs showed complete Osseointegration after 1 year of functional loading.

#### Conclusion

The present study shows promising results for immediate loading of single implants. All implant sited fulfilled success in terms of function and esthetics, and particularly promising results were seen following additional adjustments of the provisional restorations to preserve interdental papilla.



One year follow-up appearance.



Radiographs showing fracture and decayed root of maxillary left second premolar - the implant at place ment.

#### Authors' affiliations

<sup>1</sup> Private Practice, Chieti-Pescara, Italy.  
<sup>2</sup> Visiting Professor, Dental School, University of Foggia, Italy.  
<sup>3</sup> Professor and Head of Department, D'Ental School, University of Foggia, Italy.