

## Clinical Cases



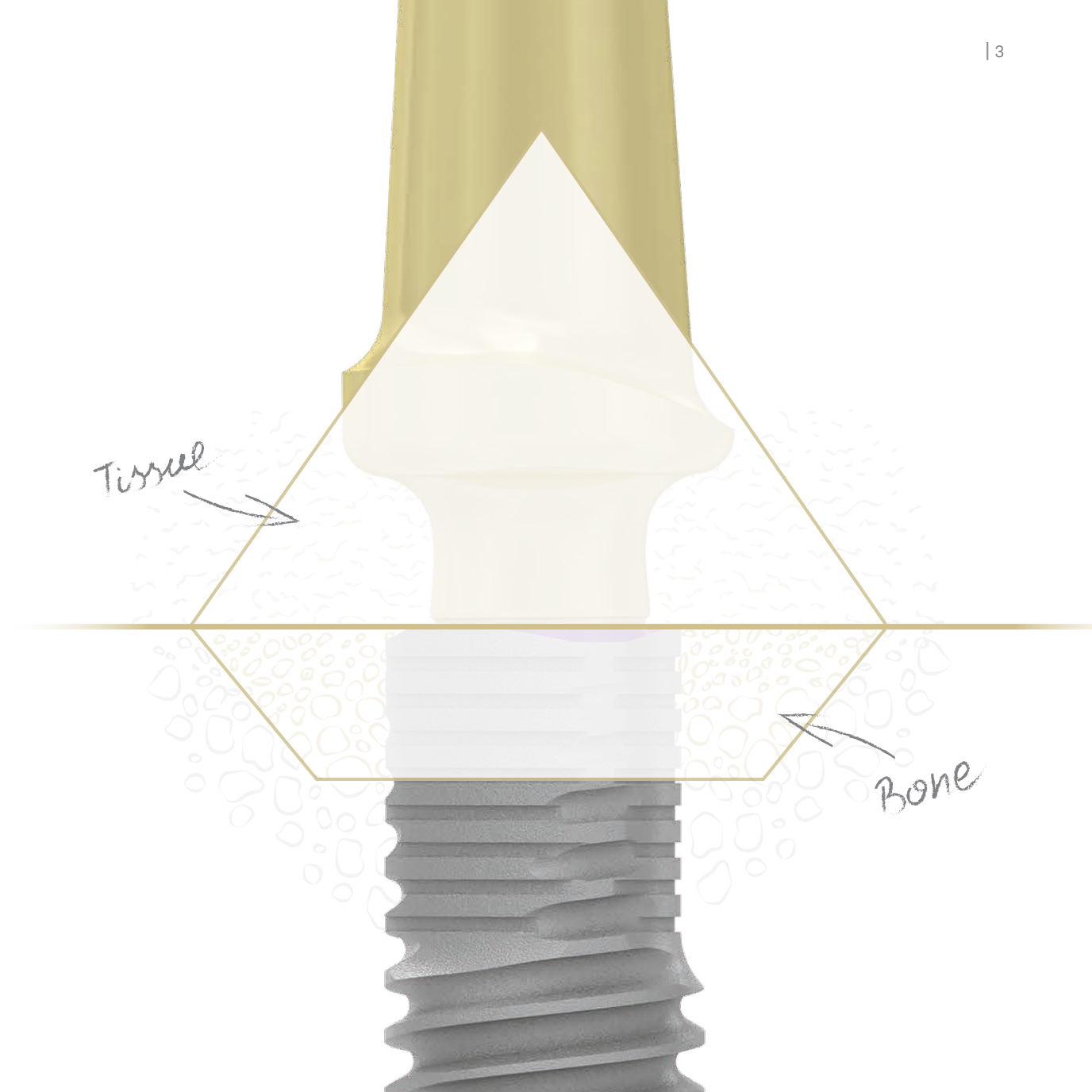
SET THE VOLUME  
OF BONE AND SOFT TISSUE

# Overview

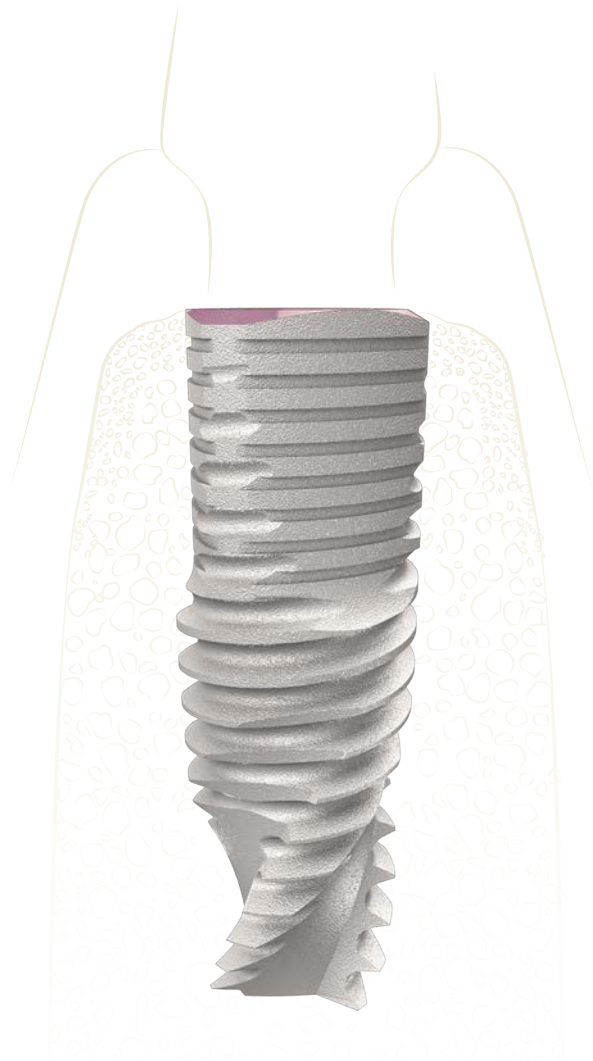
VCONCEPT is a holistic approach that involves the entire rehabilitation process: the innovative V3 implant, its advanced prosthetic system and their relationship with the surrounding tissue.

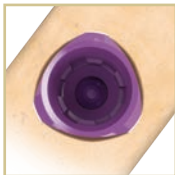Tissue

Bone



# BONE VOLUME





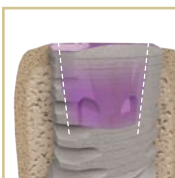
#### Implant shape

The triangular shape of the V3 neck provides high immediate crestal stability and maximum bone preservation. Anchorage is achieved at three areas without compromising crestal primary stability. The compression - free gaps provide a reservoir for blood pooling and the formation of blood clots, for faster implant integration and accelerated bone growth. Crestal bone loss is minimized by reducing stress in the cortical bone.



#### Platform switching

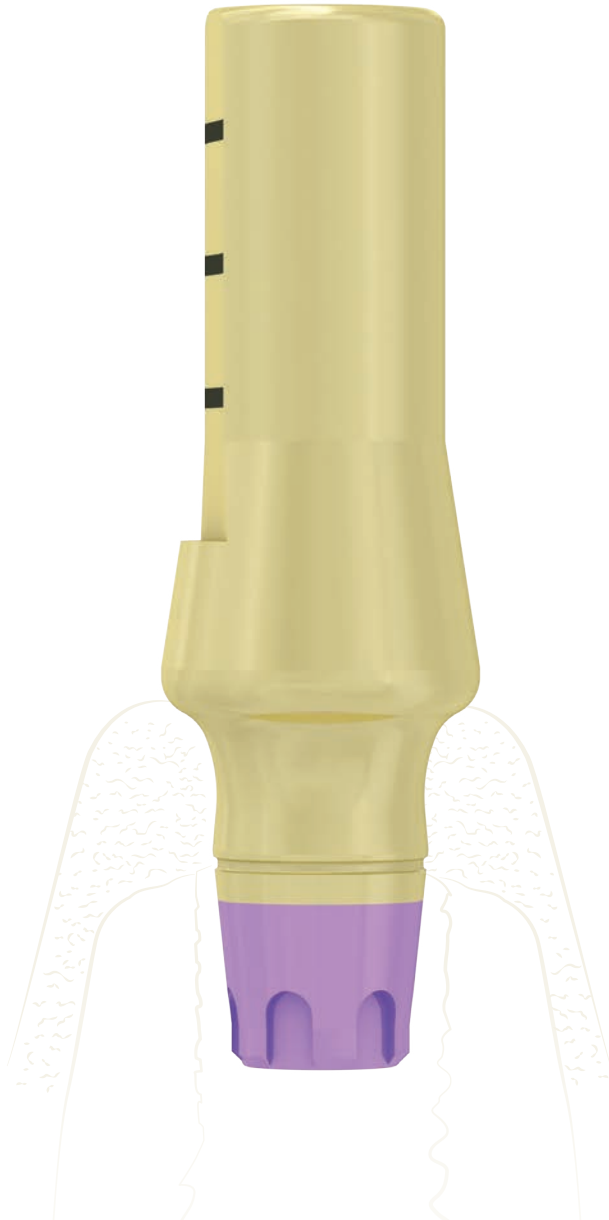
The platform switching keeps the implant - abutment connection away from the bone; minimizing bone resorption. Platform switching additionally allows more vital growth of the soft tissue.



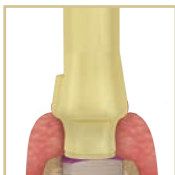#### 12° conical connection

The 12° conical connection creates an ultimate seal and ideal connection between the implant and abutment with built-in platform switching, reducing micro-movements.

TISSUE  
VOLUME

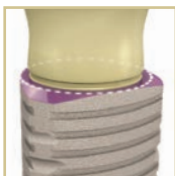





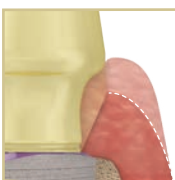#### Abutment design

A unique abutment design presents uncompromising accuracy; a consistent concave emergence profile for excellent soft tissue results; golden shade to support high esthetic results; color coding for simple and immediate platform identification and a positioning groove to ensure definite fit over the implant.



#### Platform switching

The platform switching keeps the implant-abutment connection away from the bone; minimizing bone resorption. Platform switching additionally allows more vital growth of the soft tissue.



#### Concave emergence profile

A consistent concave emergence profile throughout all prosthetic components, allows an efficient restorative procedure and extra soft tissue volume; leading to favorable esthetic results.

# Clinical Cases

## CASE 1.

Surgical part: Gustavo Giordani (Brazil)

Prosthetic part: Florin Cofar (Dentcof, Timisoara, Romania)

Technician: Edson Silva (Dentcof Lab, Timisoara, Romania)

**Patient:** 52 years old

The patient came to Dentcof-Timisoara-Romania for a check-up. We found at the tomography an internal root resorption on tooth number 22. We decided to replace the tooth with an implant. Using the alveolar model technique, we extracted #22 with minimal invasive instruments. Placed a 3,9x13mm V3 implant. We grafted with connective tissue graft and Bio-Oss and finished the surgical procedure with immediate loading.

After 3 months, Florin Cofar and Edson Silva finished her case with Zirconia abutment on number 22 and a feldispatic cemented crown on 21, 22 and a ceramic veneer on 23.

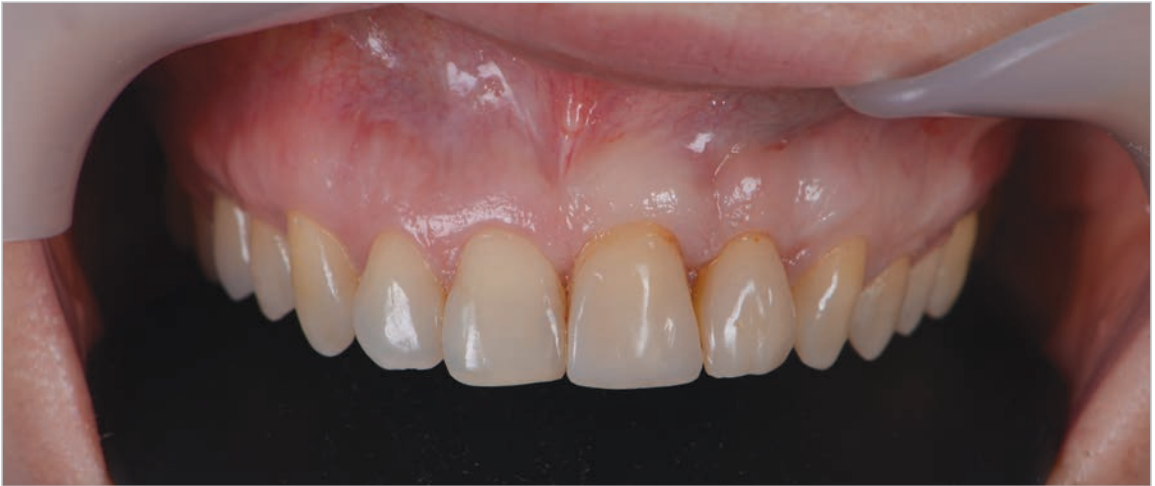

Fig. 1 Initial

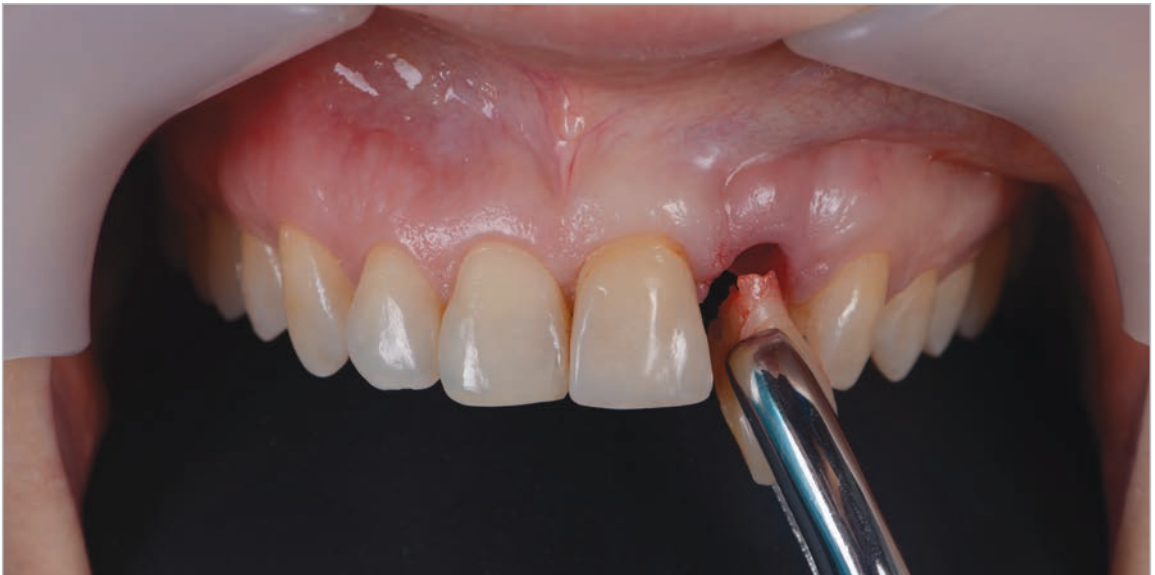

Fig. 2 Minimal Invasive extraction

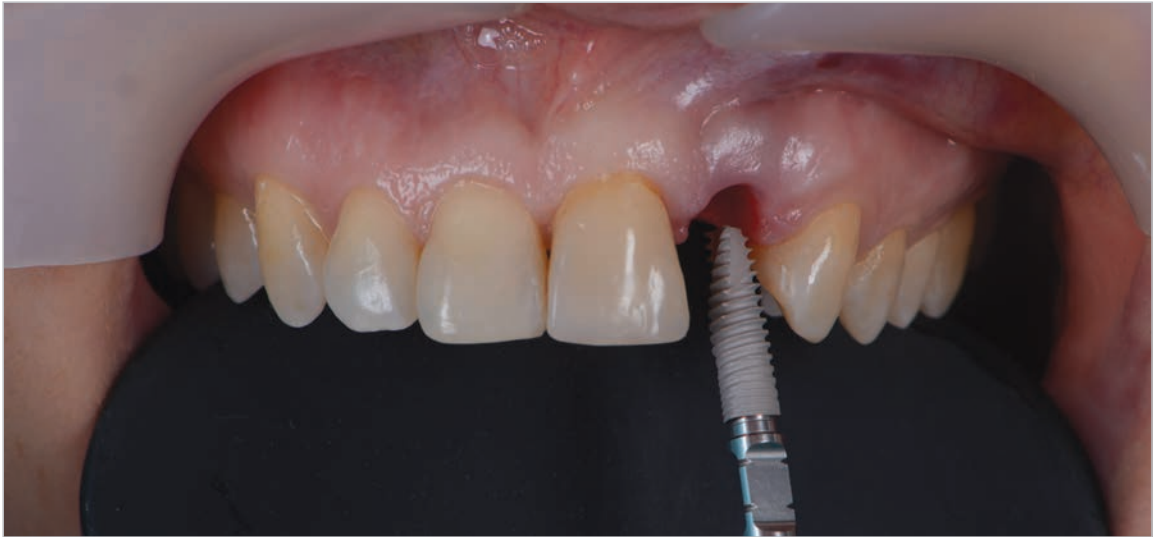

Fig. 3 V3 Implant placement

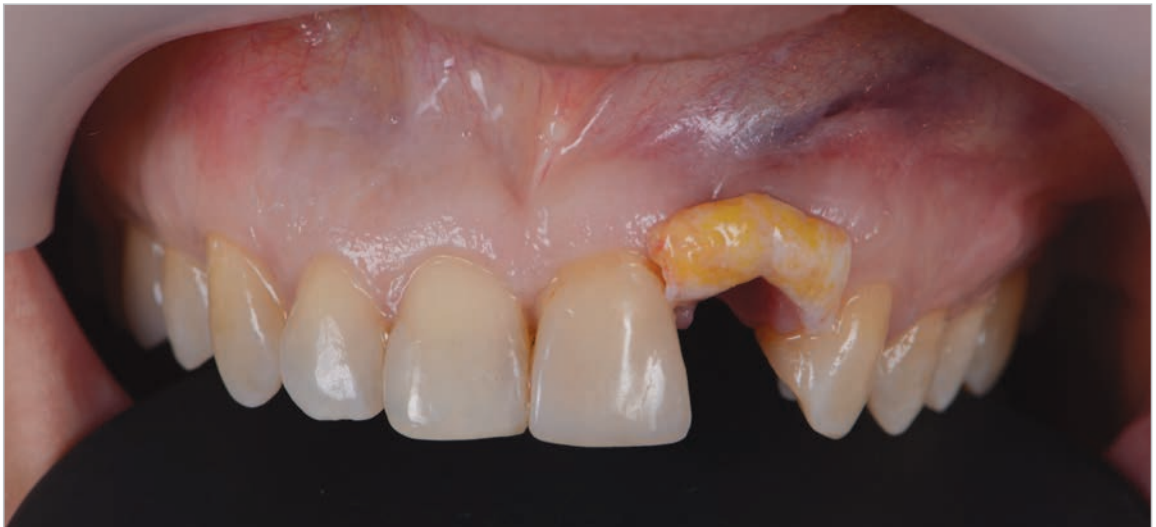

Fig. 4 Connective Tissue Graft

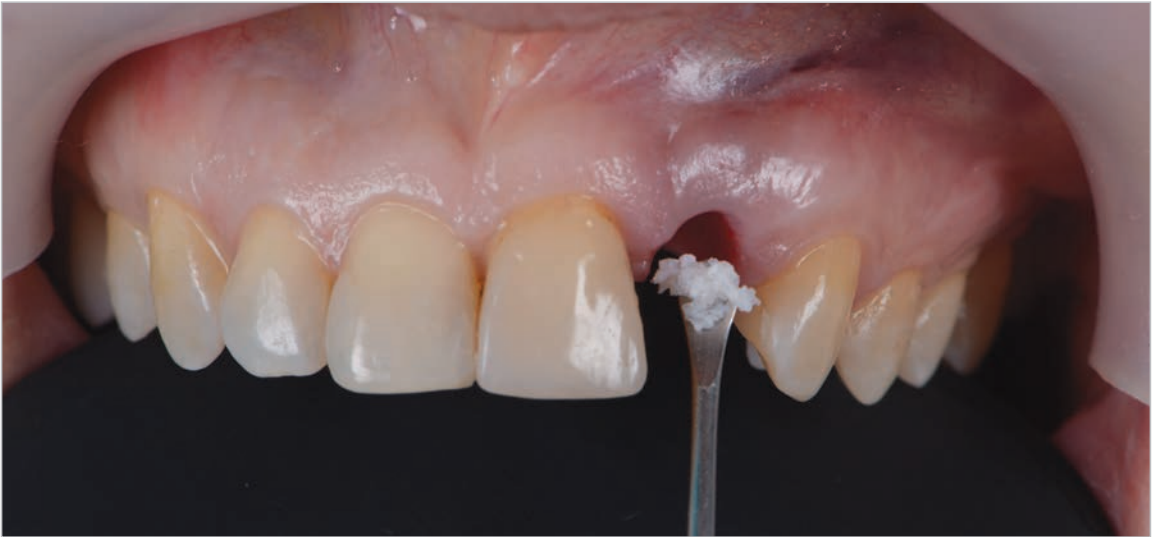

Fig. 5 Biomaterial



Fig. 6 Provisional

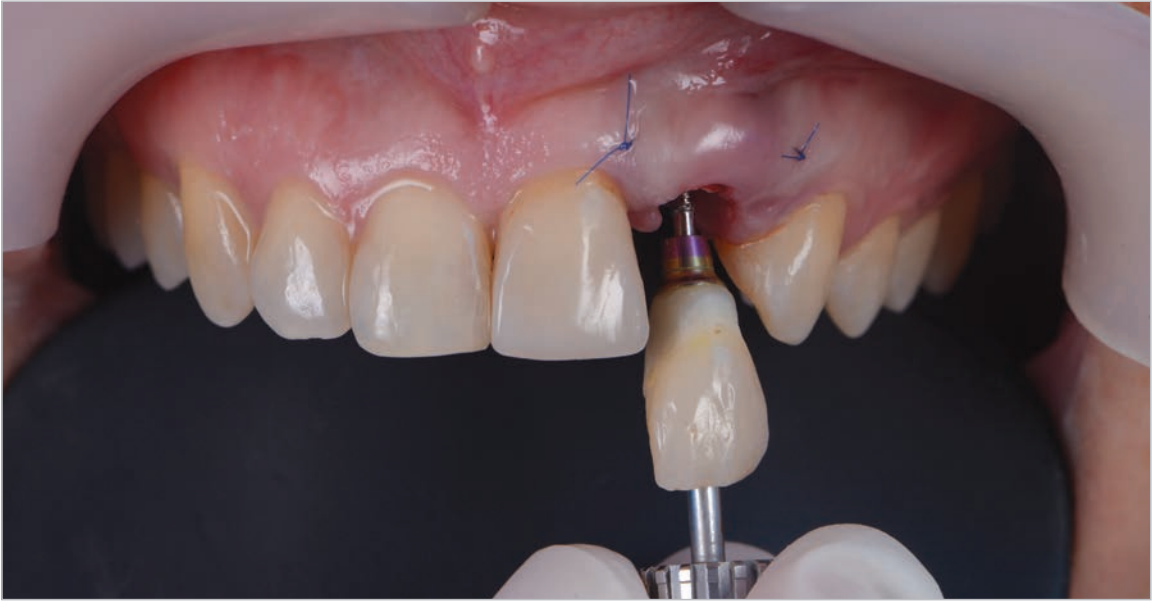

Fig. 7 Provisional Insertion

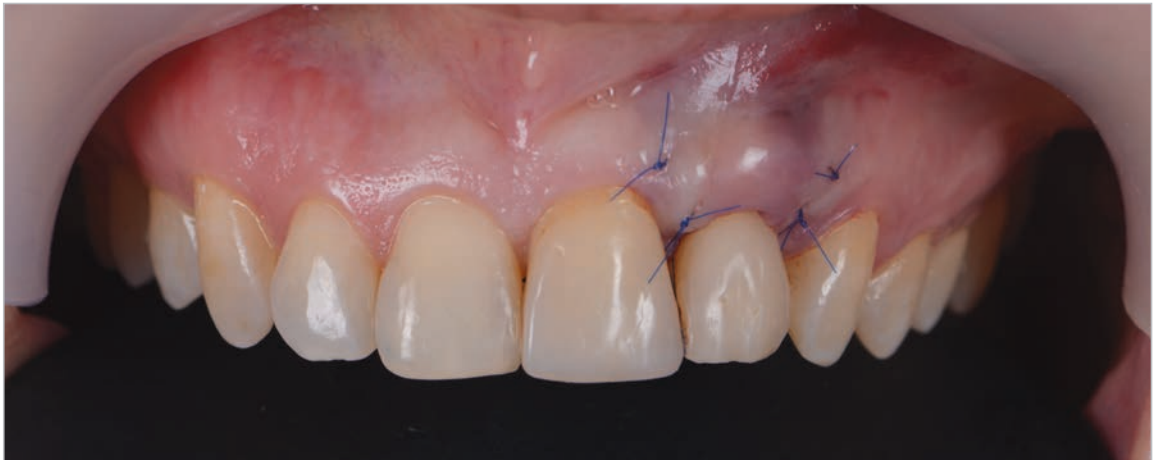

Fig. 8 Final Surgery

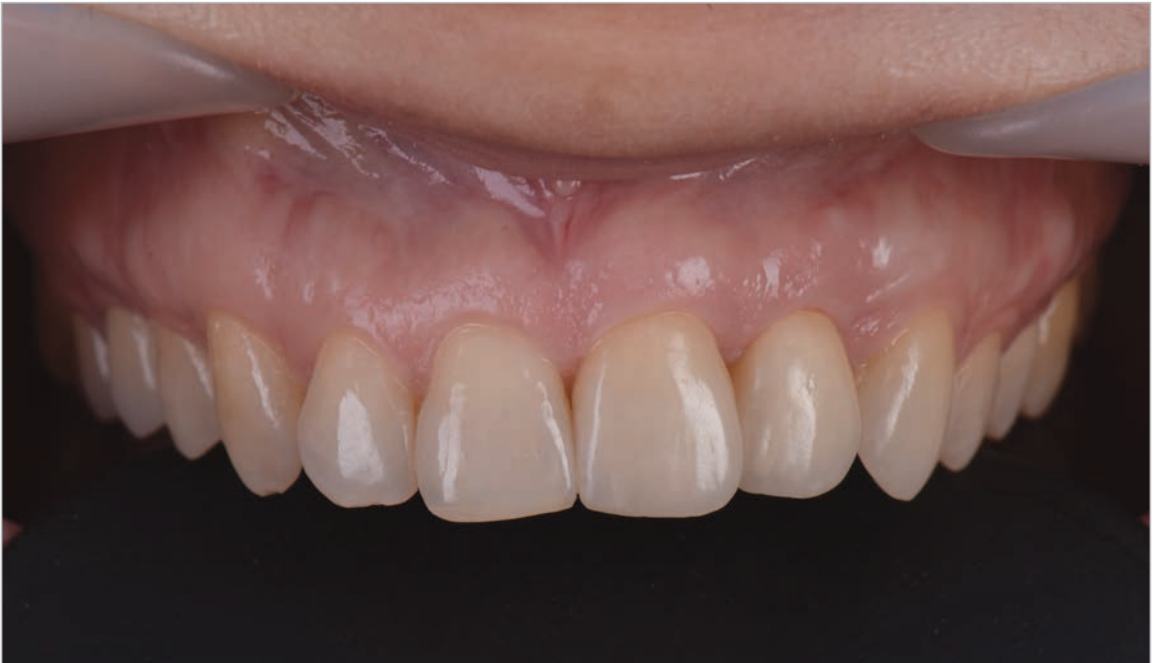

Fig. 9 Final Ceramic

## CASE 2.

Restorative Dentist: Florin Cofar (Dentcof, Romania)

Surgeon: Eric Van Dooren (Antwerp, Belgium)

Dental Technician: Loana Popp (Dentcof, Romania)

Also contributed: Ioan Cofar, You Nino,  
Alin Dinca, Mihai Simonia

**Patient:** Andrada, 21 years old

Diagnosis: Deciduous Canines, Unhappy about her smile. Treatment: Crown lengthening, Guided surgery (MGUIDE ), Extraction and V3 Implants ( Tooth number 13 and 23 ) with soft tissue grafting followed by Monolithic restorations ( Empress CAD Multi Block ) using SKYN concept on tooth 25 to 15.





Fig. 1 Patient is a 21 year old model, concerned and unhappy about her smile.

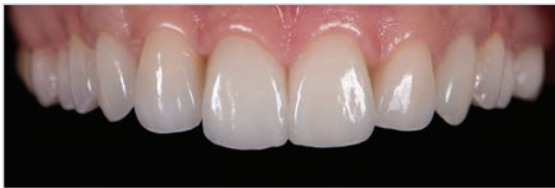
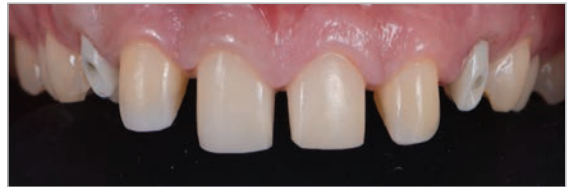
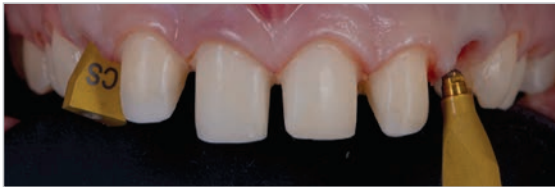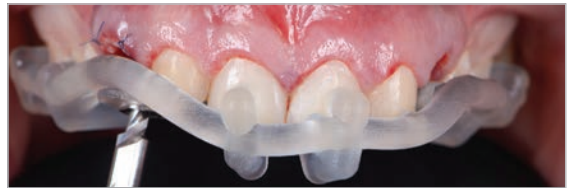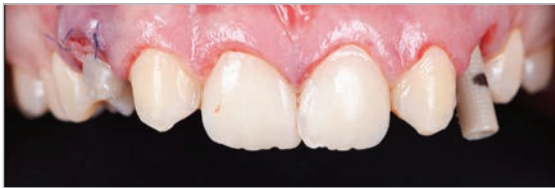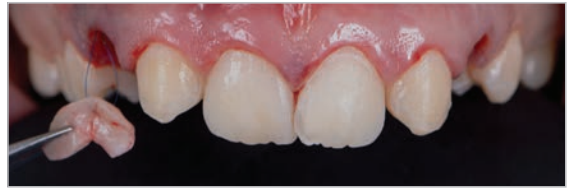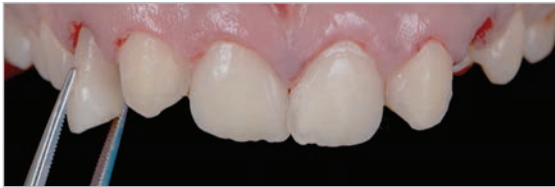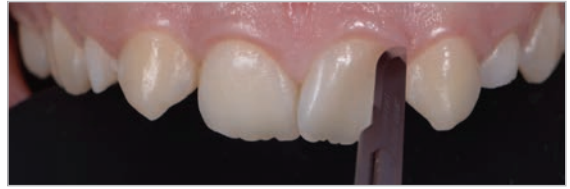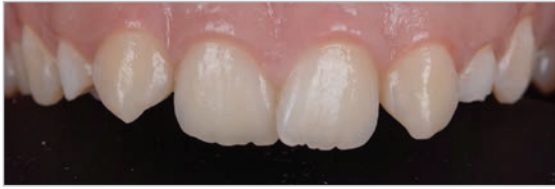Fig. 2 Case is guided by DSD (Digital Smile Design) that helps us determine the tissue level, and vertical implant position. Case execution is a rehearsal of the digital planning.

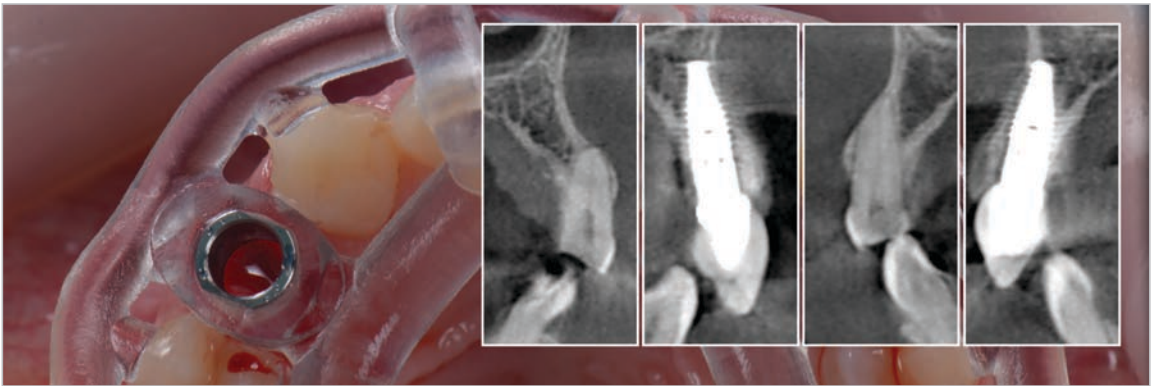


Fig. 3 3D implant position is planned with MSOFT, and surgically performed using MGUIDE.

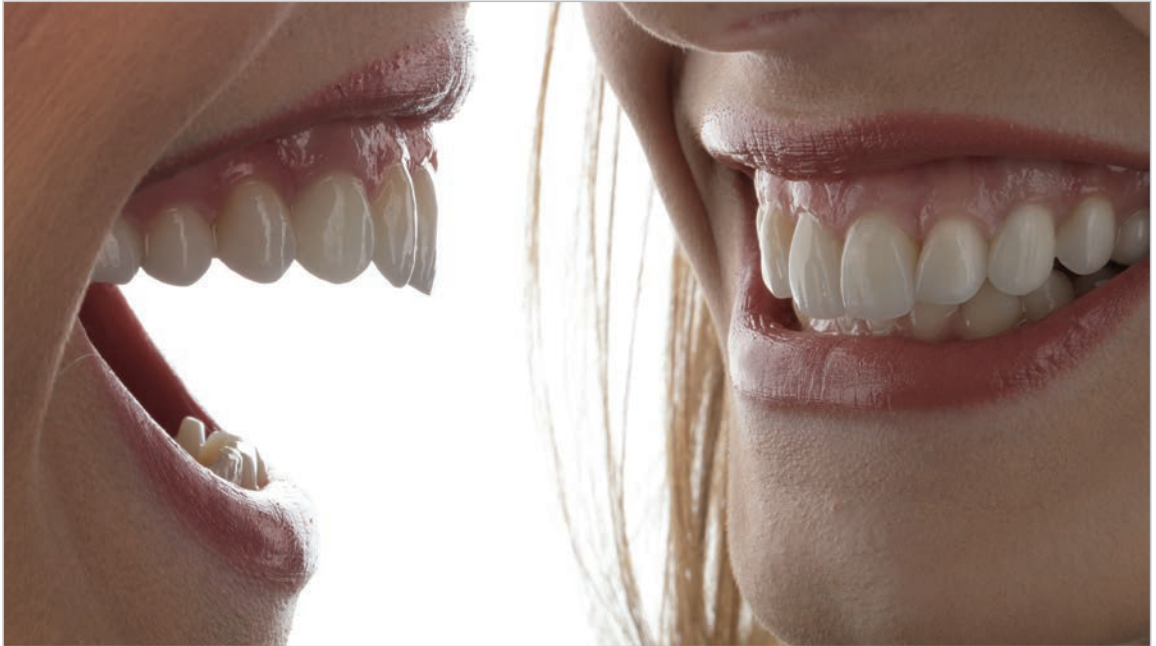

Fig. 4 Final restoration and tissue integration

Fig. 5 Final smile. Happy patient >





### CASE 3.

Surgeon: Tommie Van de Velde (Mond@Medipolis, Antwerp, Belgium)

Prosthodontist: Alexander Declerck and Vincent Bielen

Technician: Benedikt Vernailen (Lab@Mond, Antwerp, Belgium)

Emergency treatment: Annelien Verhelst

Endodontist: An Van Kerkhoven

**Patient:** 24 years old

The patient (M.R.), 24 years old, presented for the first time in our office in 2011 on a sunday afternoon with an emergency. He is a professional basketball player and was hit with an elbow that resulted in avulsion of teeth 21 and 22. Appropriate treatment was performed the same day and following weeks. Follow-up radiographs (figure 2) showed resolution both teeth, however beginning of 2015 signs of internal resorption were visible on radiographs. The patient had disturbing sensitivity but clinically no signs of inflammation were visible around the resorbing 21 (Figure 1-3).

The idea was to replace part of the tooth that was failing to preserve surrounding tissues (socket shield technique) with a V3 implant. A zirconia abutment was prefabricated based on the pre-surgical planning (MGUIDE). A MIS V3 4,3 x 13 mm implant was placed. The triangular shape of the coronal part of the implant leaves a space between the remains part of the root and the implant for bone formation (Figure 4-5). A connective tissue graft was placed to increase mucosal thickness on the buccal side of the implant.

The definitive abutment was tried and bonded to a lithium-disilicate coping that allows adhesive bonding. The buccal part of the extracted 21 was prepared to veneer the definitive abutment (Figure 6). This results in an immediate restoration with a one-abutment-one time concept: biocompatible Zirconia submucosally, lithium-disilicate layering and an autologous veneer. The socket shield, together with the biocompatible materials results in a maximal preservation of peri-implant tissues (Figure 7). Figure 8 shows the clinical situation after 5 weeks. This semi-provisional implant restoration can last on a long-term basis. If the autologous veneer fails, a new ceramic veneer can be bonded after preparation onto the lithium-disilicate layer. If a more profound adaptation of the abutment is needed, the zirconia abutment can be unscrewed with consecutive prosthetic treatment on implant level.

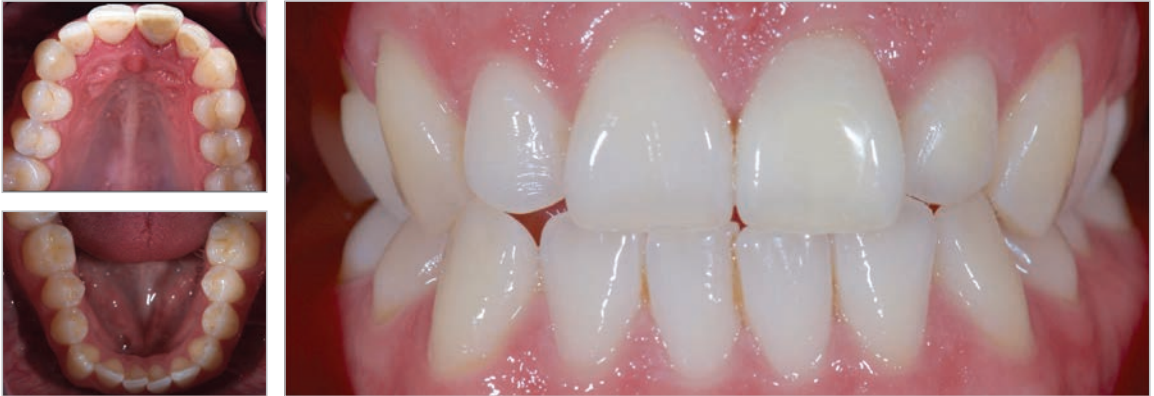

Fig. 1 Pre-operative occlusal and frontal images (January 2015).

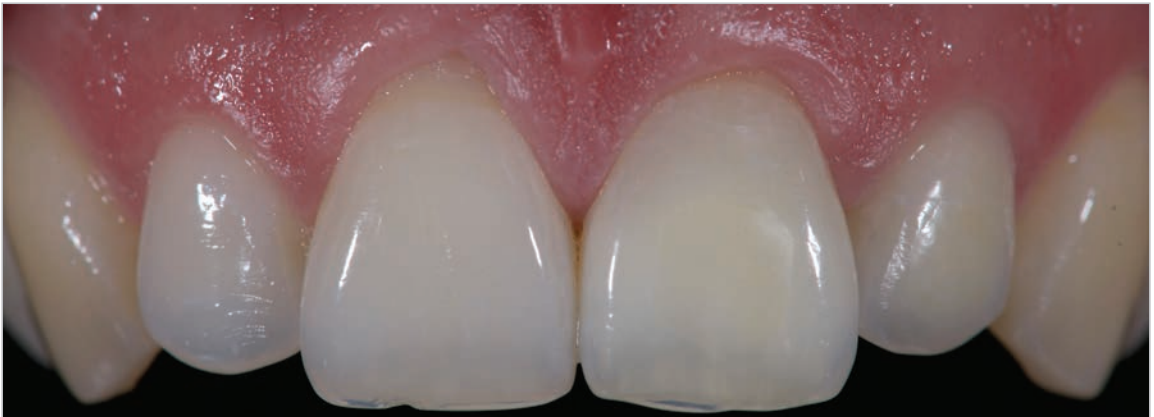

Fig. 2 Frontal image of the maxillary anteriors without any clinical signs of infection.

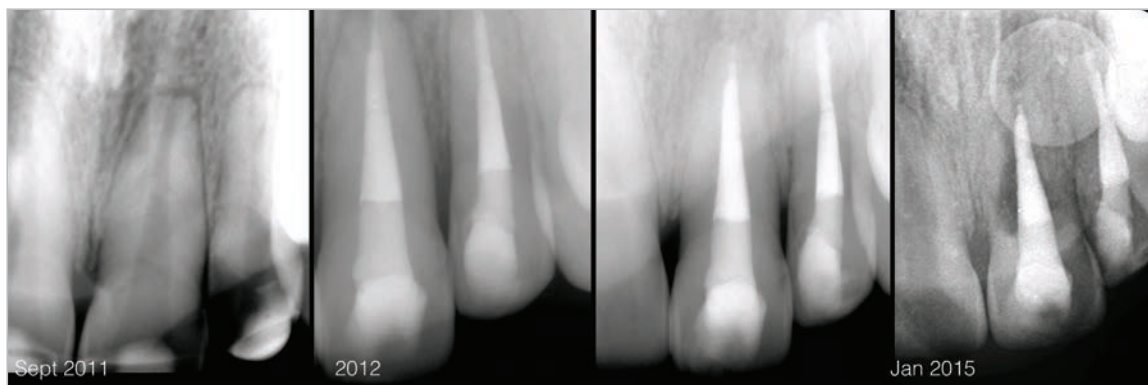


Fig. 3 Peri-apical radiographs from 2011-2015 (pre-operative)

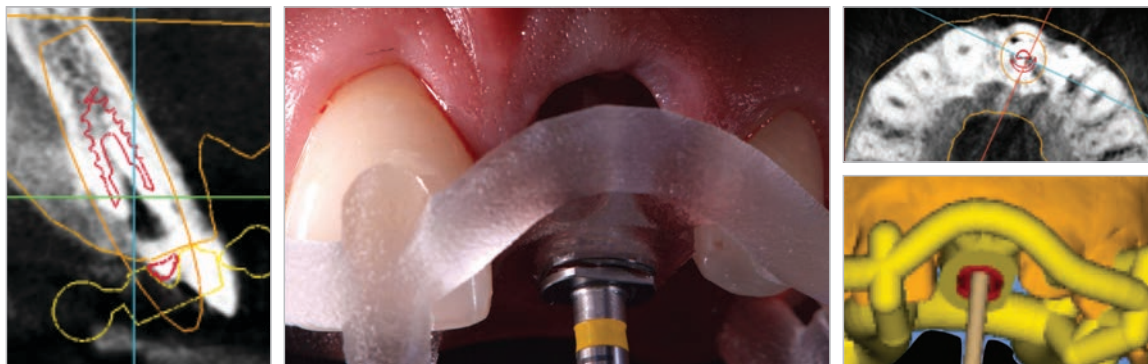

Fig. 4 Pre-surgical planning (MSOFT, MIS, Israel) and clinical view of the MGUIDE to facilitate precise implant positioning.



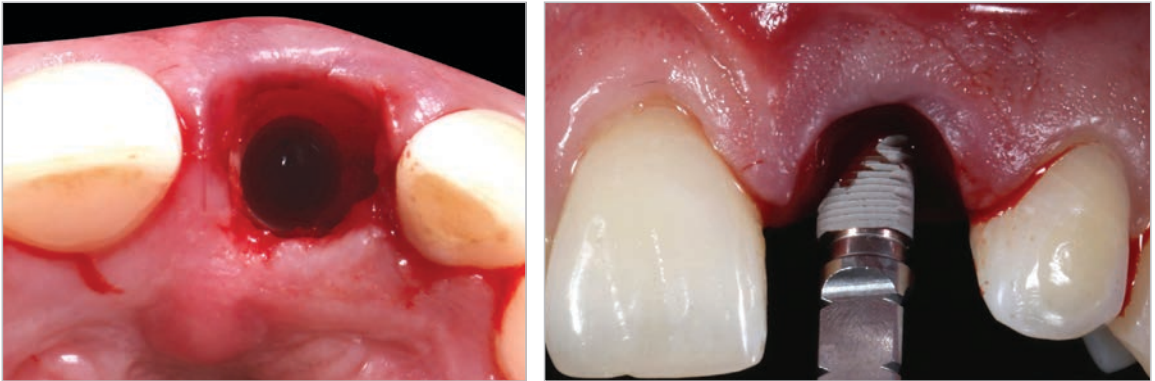


Fig. 5 Left: occlusal view of the alveolar socket with buccal part of the root (socket shield technique) present. Right: V3 (MIS, Israel) implant insertion.

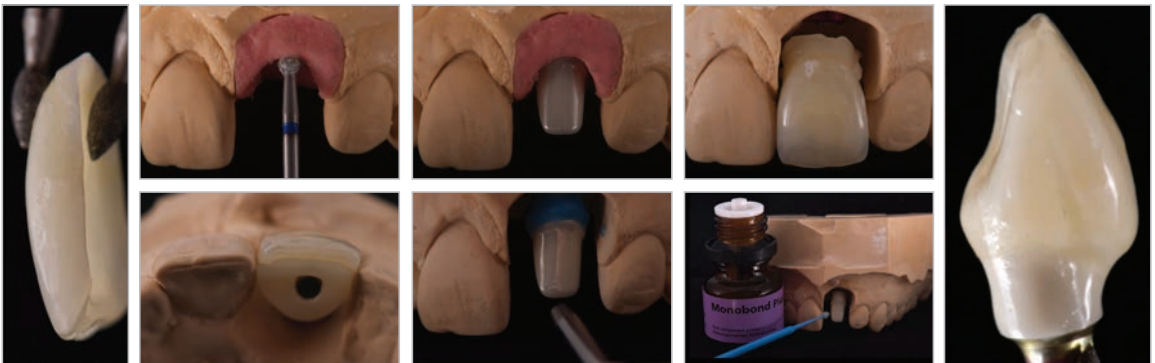

Fig. 6 Overview on the laboratory procedure to adhesively bond the autologous veneer to the zirconia abutment (lithiumdisilicate interface).

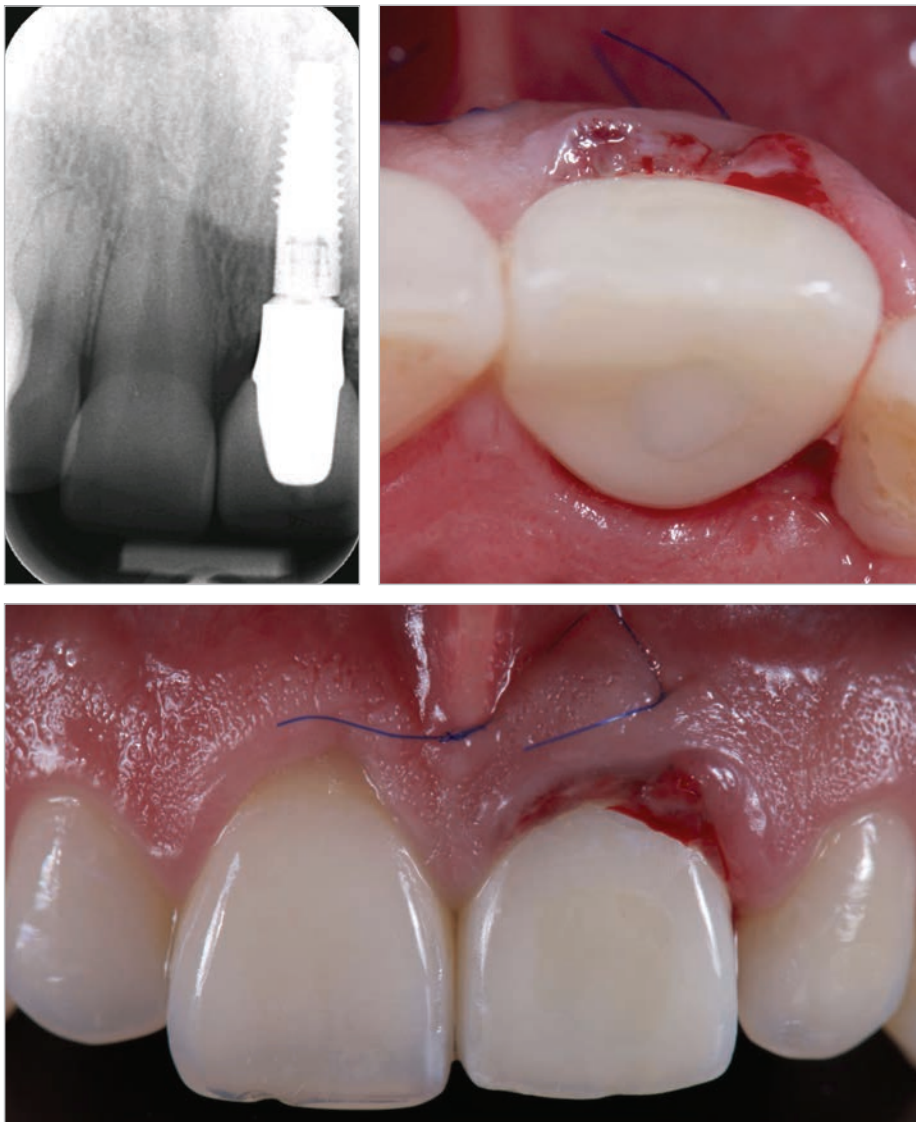


Fig. 7 Post-operative radiograph and clinical images.

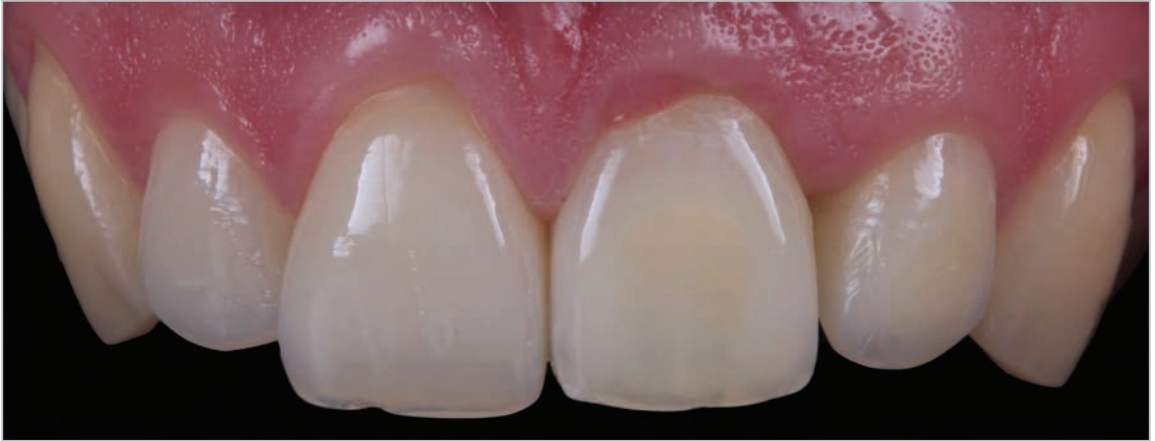

Fig. 8 Maxillary anteriors 5 weeks post-operative.

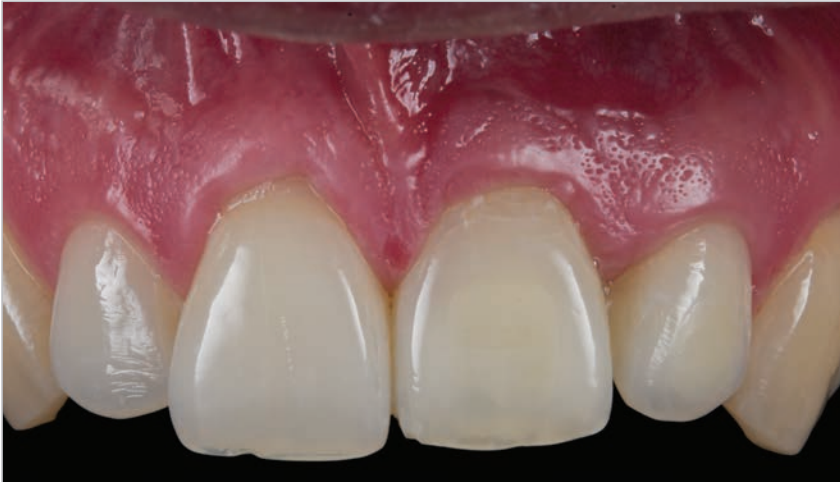

Fig. 9 Maxillary anteriors 14 months post-operative.

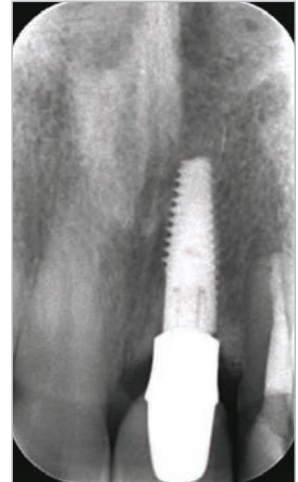

Fig. 10 Radiograph 14 months post-operative.

## CASE 4.

Surgeon: Mithridade Davarpanah (France)

Restorative Dentist: Philippe Rajzbaum

Dental Technician: Nicolas Millièrè

**Patient:** 48 years old

A 48 year-old male patient attended because of recurrent decementation of his prosthetic crown on tooth #21. Clinical and radiographic examination revealed that the loss of integrity of the root is what impaired stabilizing the prosthetic crown. Extraction and subsequent implant therapy were indicated.

During extraction, the vestibular bone lamella remained unexpectedly attached to the removed root. The original implant placement-immediate temporization procedure was cancelled; instead a preservation crest with delayed implant procedure was implemented. A Maryland bridge served the purpose of temporization.

After 6 months of healing, a V3 implant of Ø4.3 x 13 mm was placed in the preserved crest; in addition, the site was over-contoured with BioOss. Another 6 months healing period was allotted before placing the temporary crown. Two months later, the final implant-supported crown was placed simultaneously with an adjacent porcelain veneer. By the end of the treatment, a highly pleasant esthetic result with an adequate emergence profile was successfully achieved.

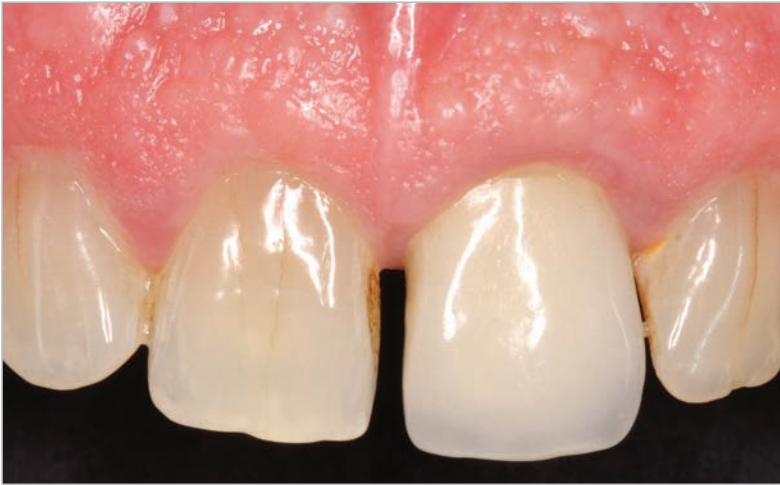

Fig. 1 Prosthetic single crown at site #21 undergoing recurrent decementation.

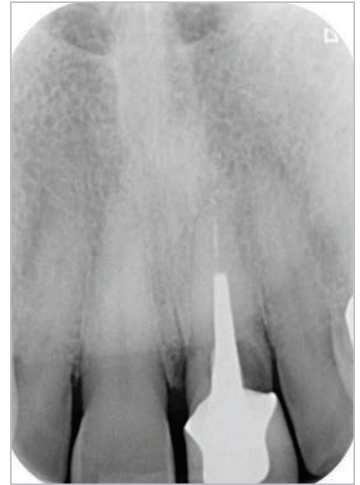

Fig. 2 Radiograph of tooth # 21 showing a loss of radicular integrity.

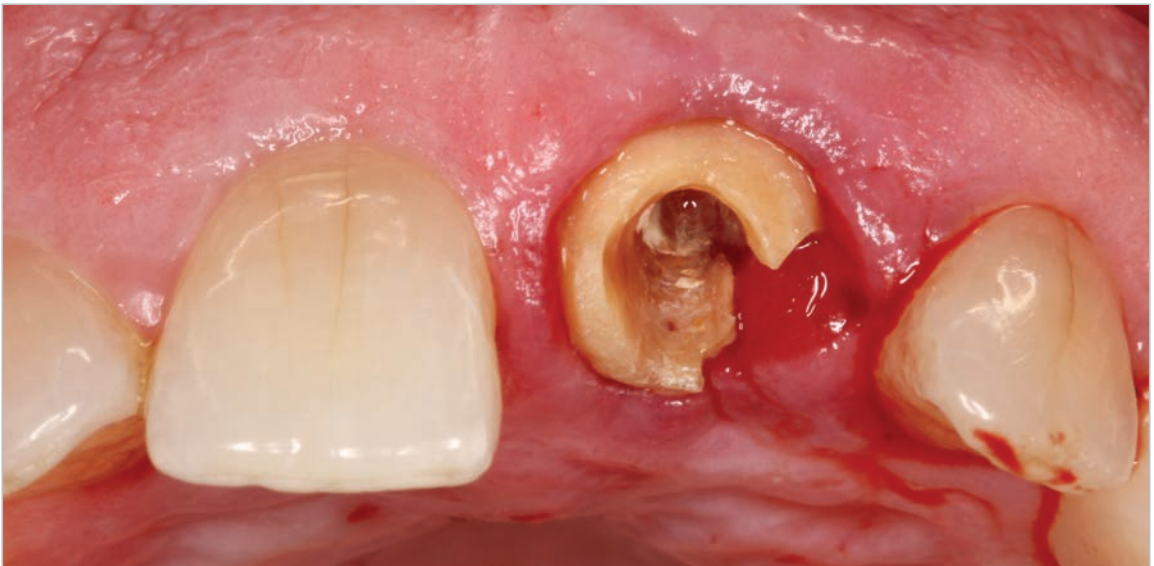


Fig.3 Occlusal view of the decayed root that is unable to provide stability to the prosthetic crown.



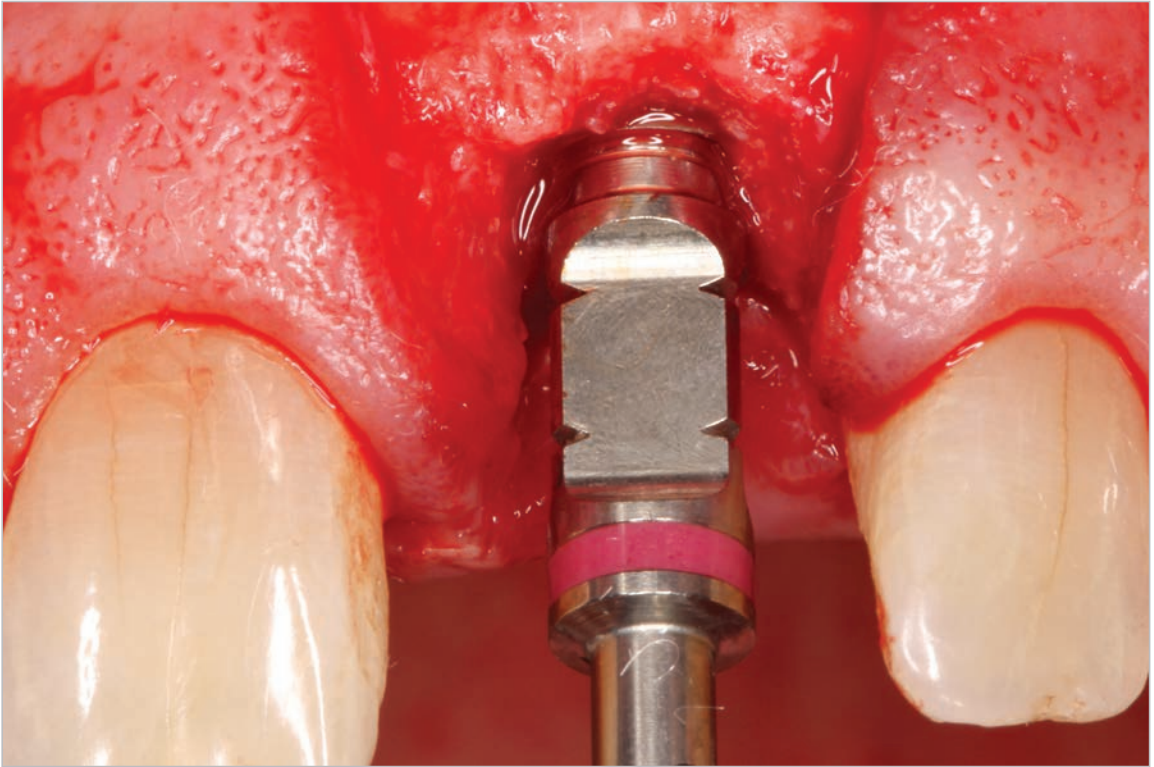


Fig 4 Implant placement of a V3 implant in the preserved crest. The flat part of the neck is parallel to the vestibular cortical lamella as witnessed by the flat part of the implant-holder.

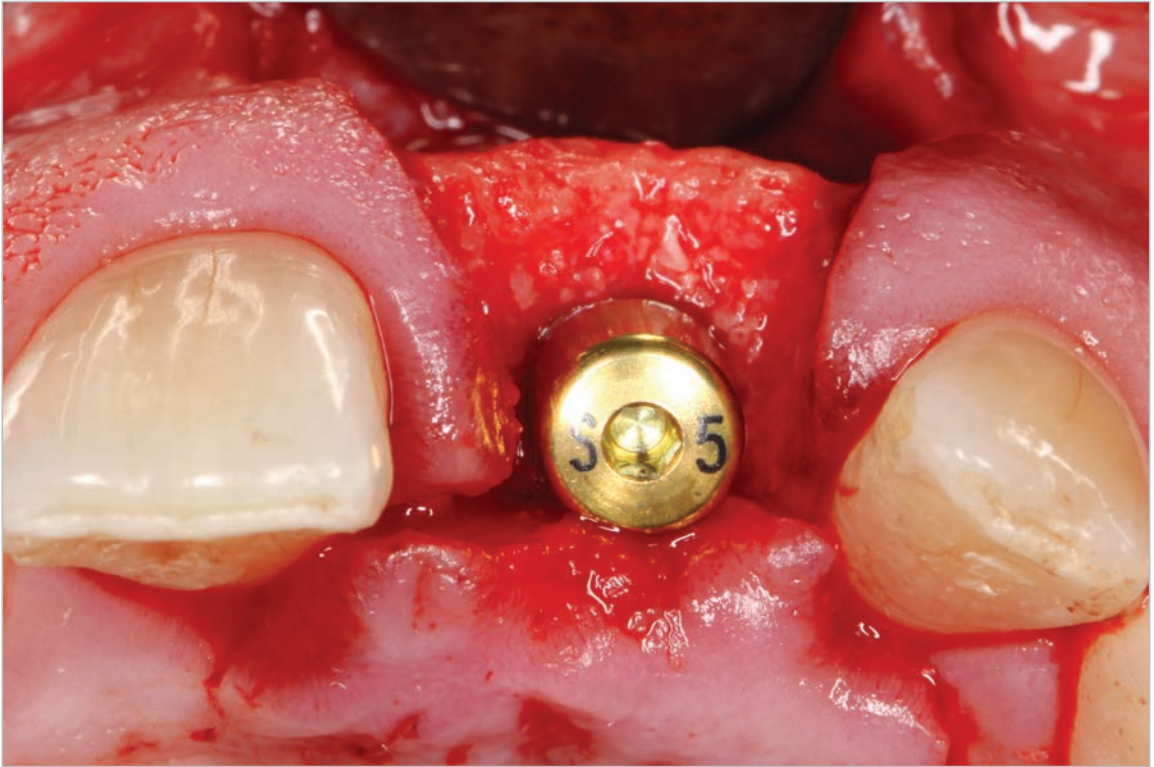


Fig. 5 Occlusal view of the V3 implant with its healing abutment. Note the width of the achieved vestibular bone lamella.

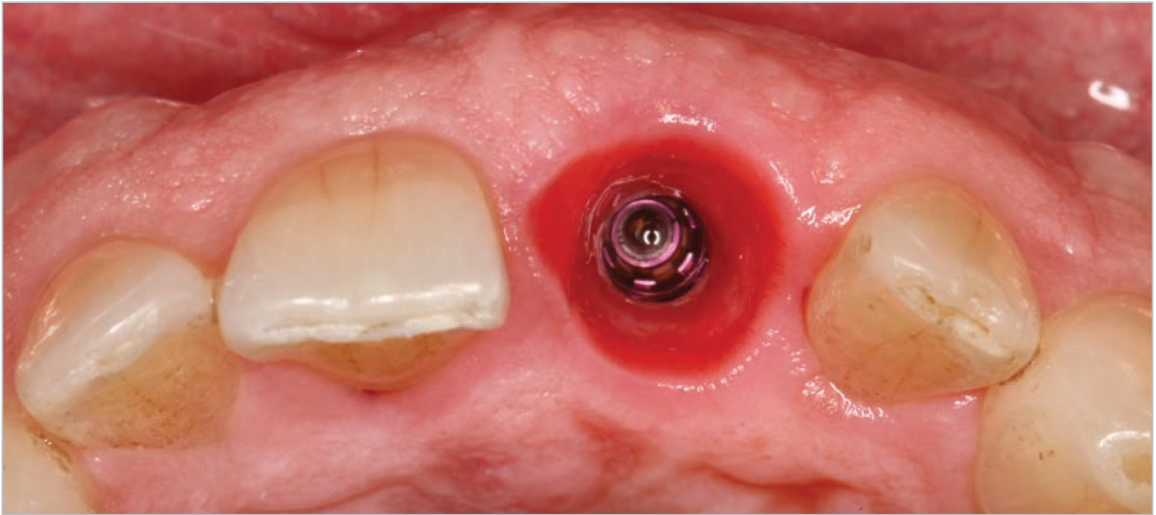


Fig. 6 Occlusal view of the emergence profile obtained with the temporary crown at impression taking. Note the shape of the vestibular gingiva at the treated site.

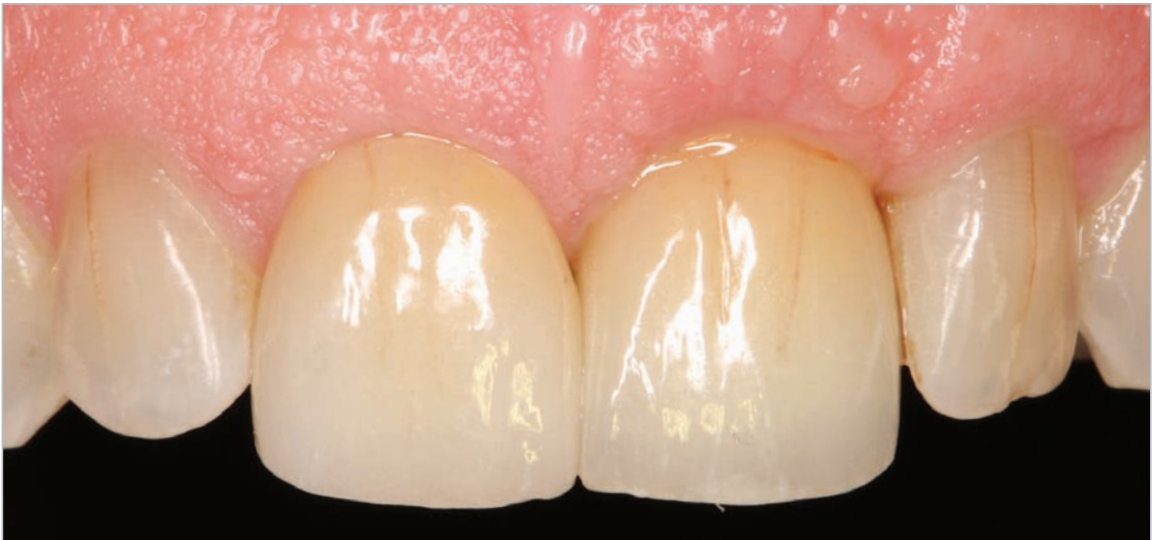

Fig. 7 View of the final implant-supported crown and the adjacent porcelain veneer.



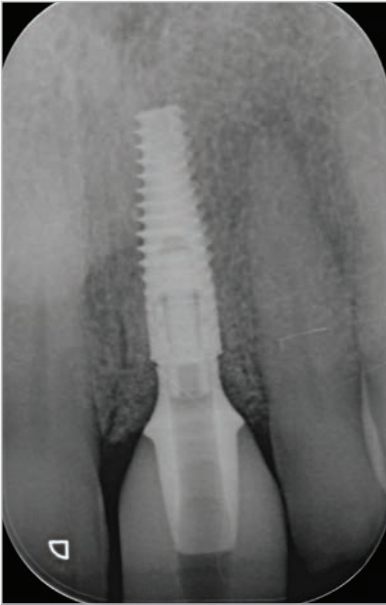


Fig. 8 Radiographic control at final crown placement. Note the bone levels adjacent to the prosthetic abutment.

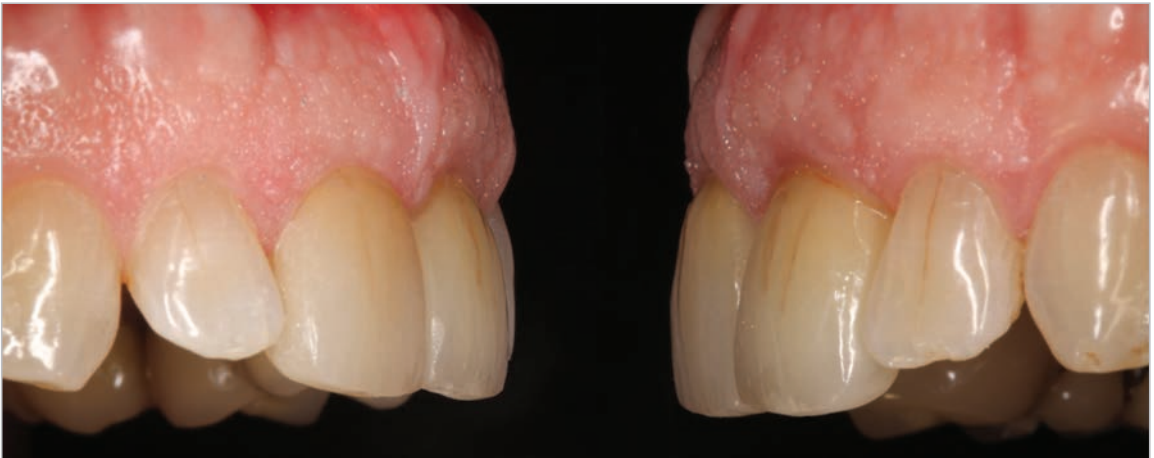

Fig. 9 Left and right lateral views of the esthetic result of the treatment.

## CASE 5.

Surgeon: David García Baeza (CIMA DENTAL, Madrid, Spain)

Prosthodontic: David Garcia Baeza

Technician: Calos Saavedra (CS LAB, Madrid, Spain)

**Patient:** 62 years old

The patient was a 62-year-old female, non-smoker with no remarkable disease. The patient presented 4 old crowns in the four anterior incisors. She was looking to improve the esthetic result changing the prosthetics and she also mentioned some pain in the upper right central incisor.

Upon exploration with a periodontal probe, we detected a root fracture obliging us to make the extraction of that tooth. After this finding, the treatment proposed was to change the four anterior crowns and rehabilitate the central incisor with an implant and a soft tissue graft. During healing period we used a four-unit acrylic bridge for the provisional restoration.

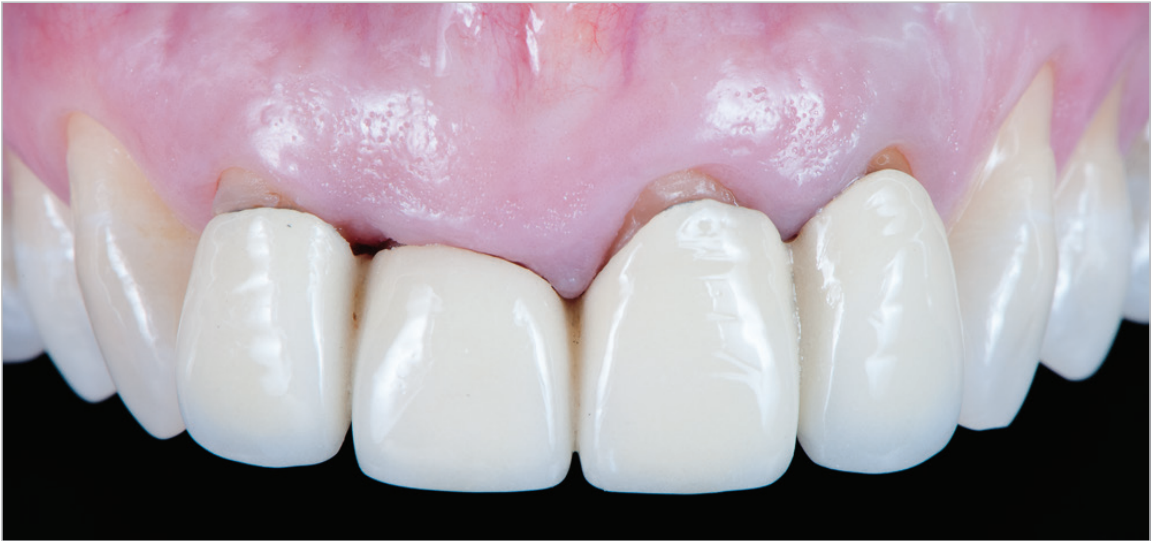

Fig. 1 Baseline.

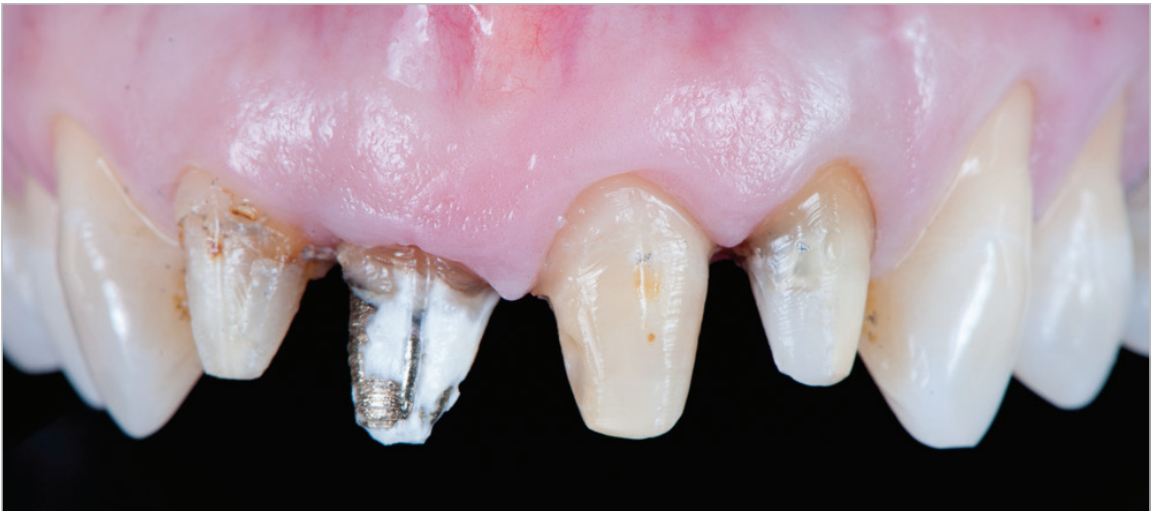

Fig. 2 Initial situation without old crowns.

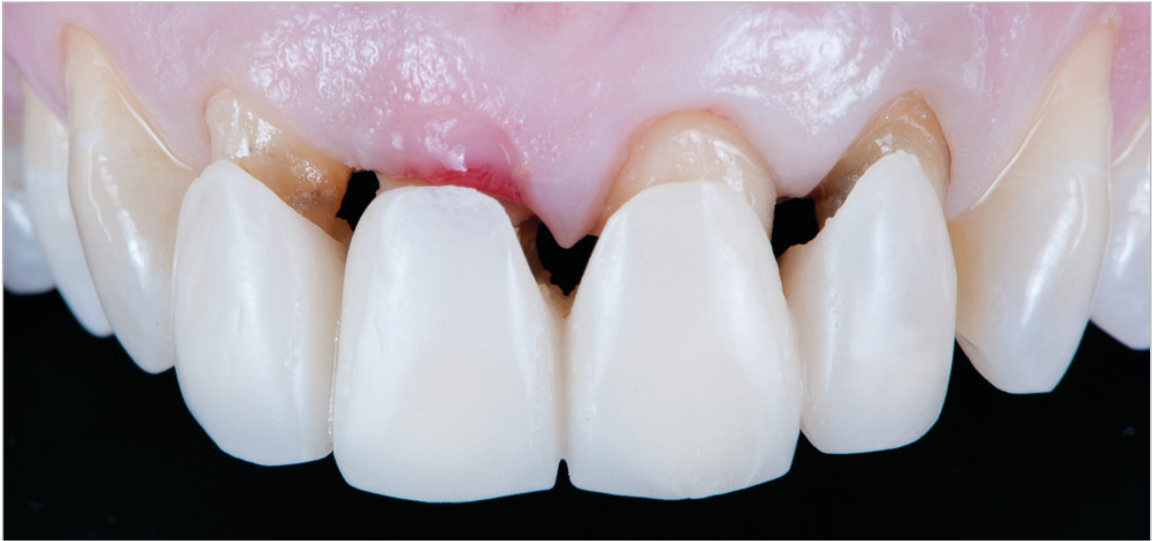

Fig. 3 Provisional restorations.

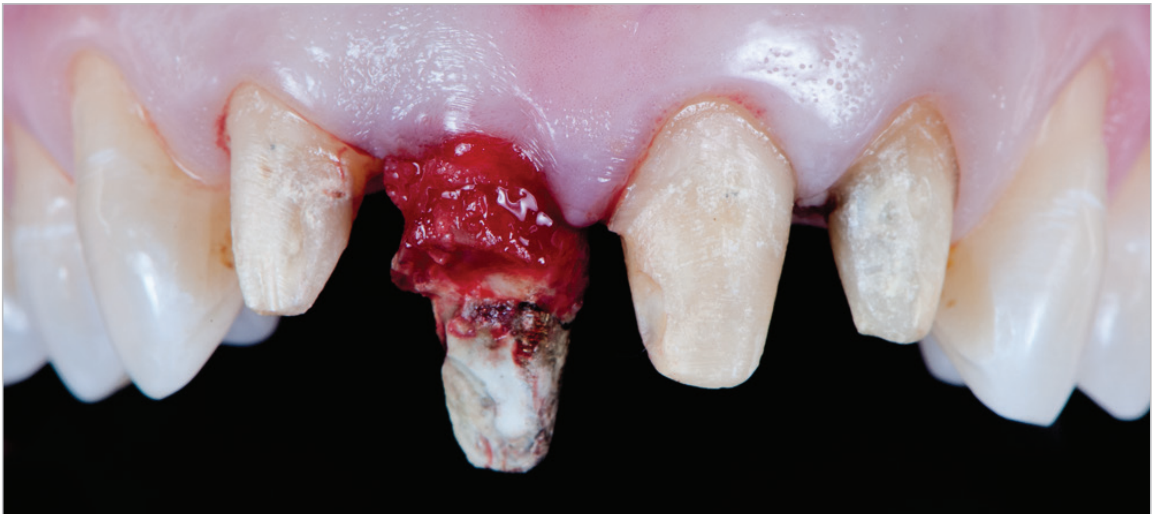

Fig. 4 Fractured tooth extraction.

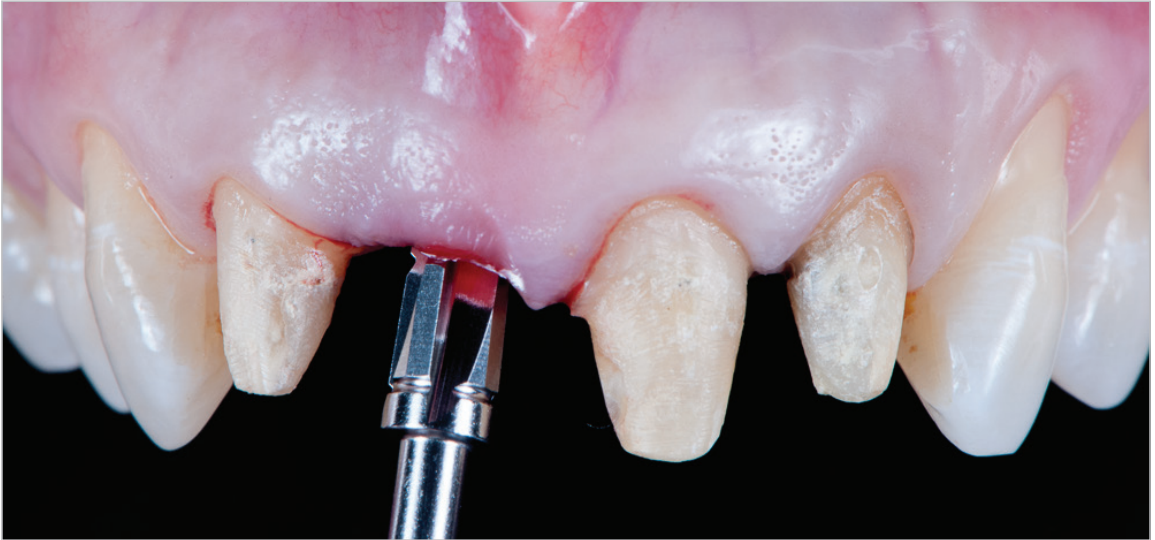

Fig. 5 Drilling.



Fig. 6 V3 final drill.

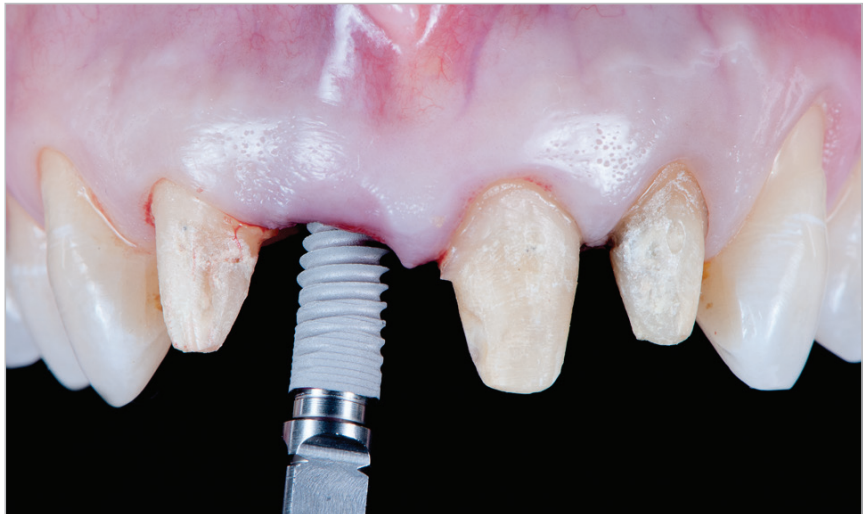

Fig. 7 V3 implant placement.



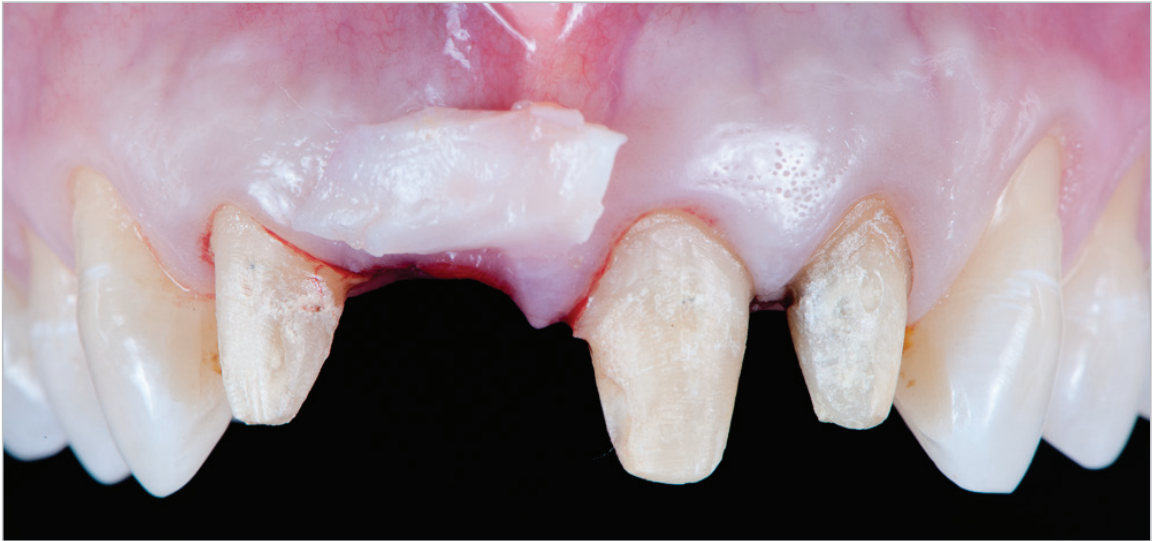

Fig. 8 Soft tissue graft.

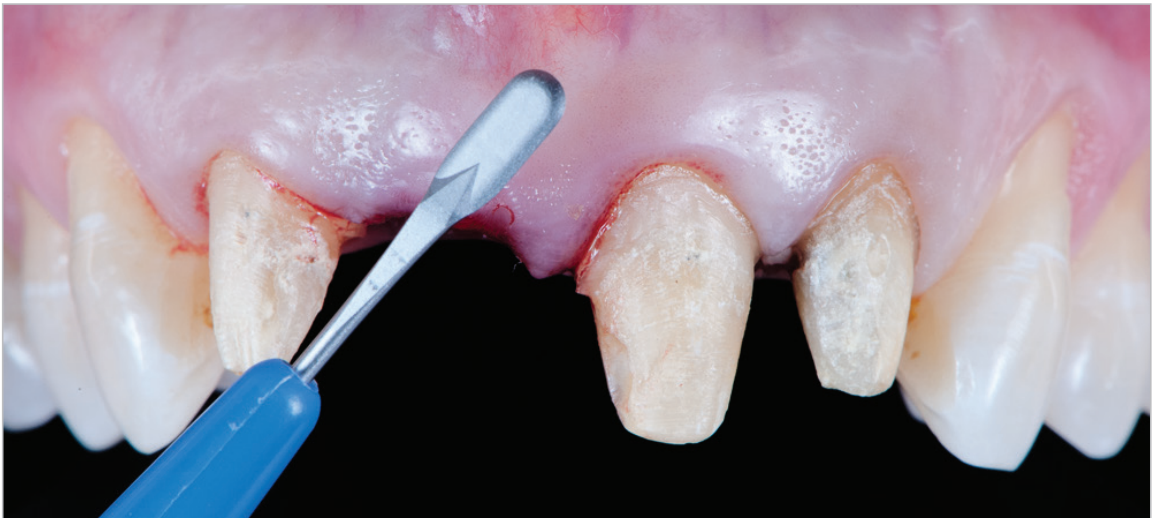

Fig. 9 Pocket incision for graft placement.

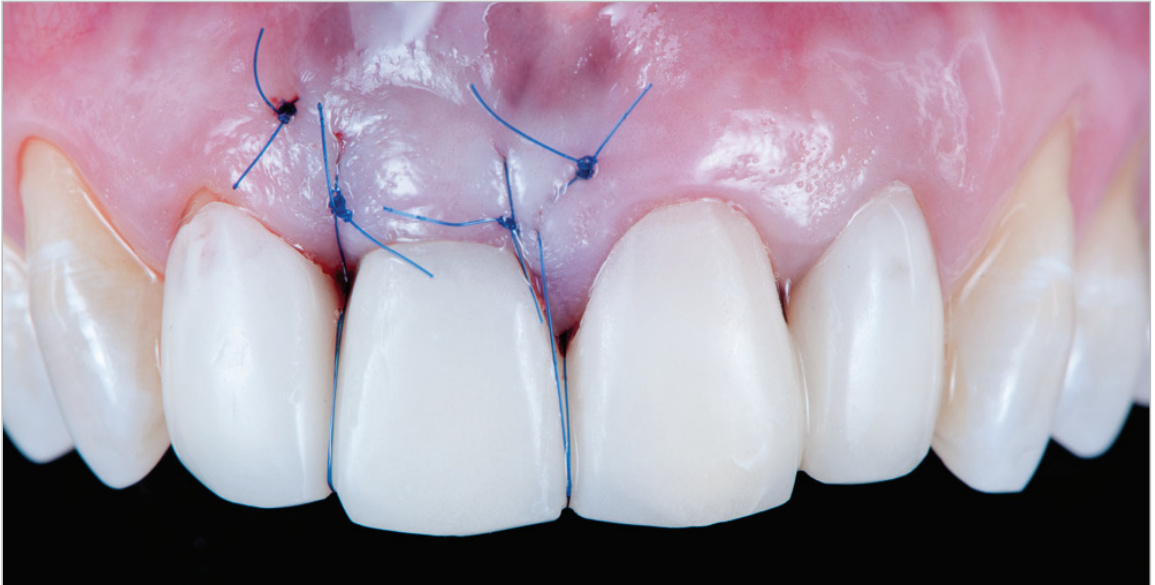

Fig.10 Final monofilament suture.

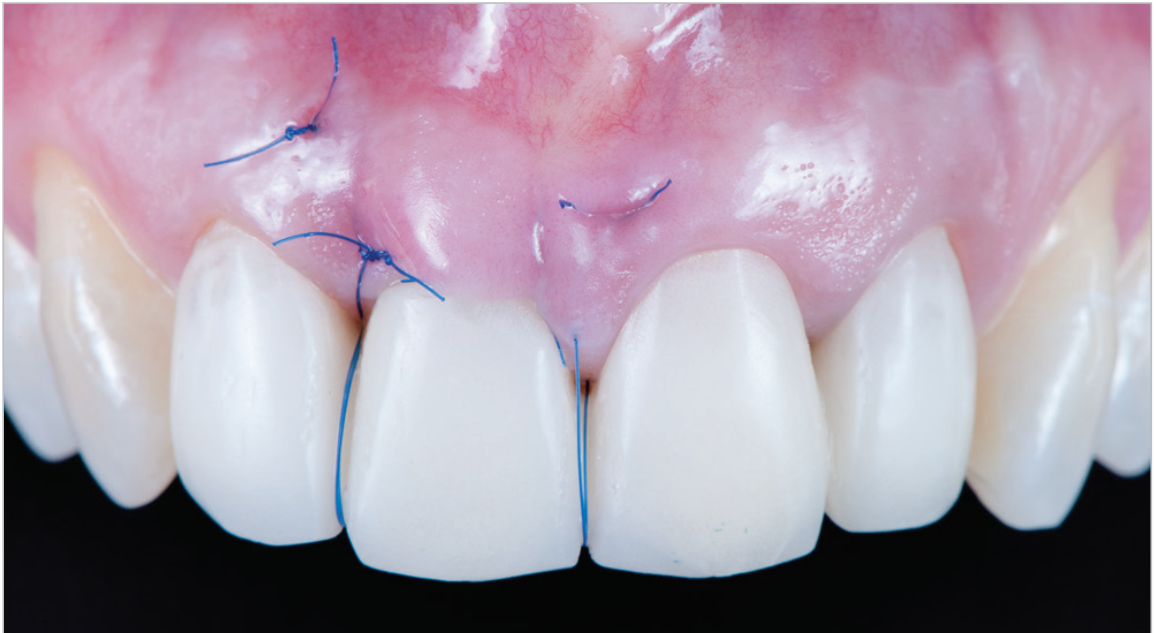

Fig. 11 2 weeks after healing.



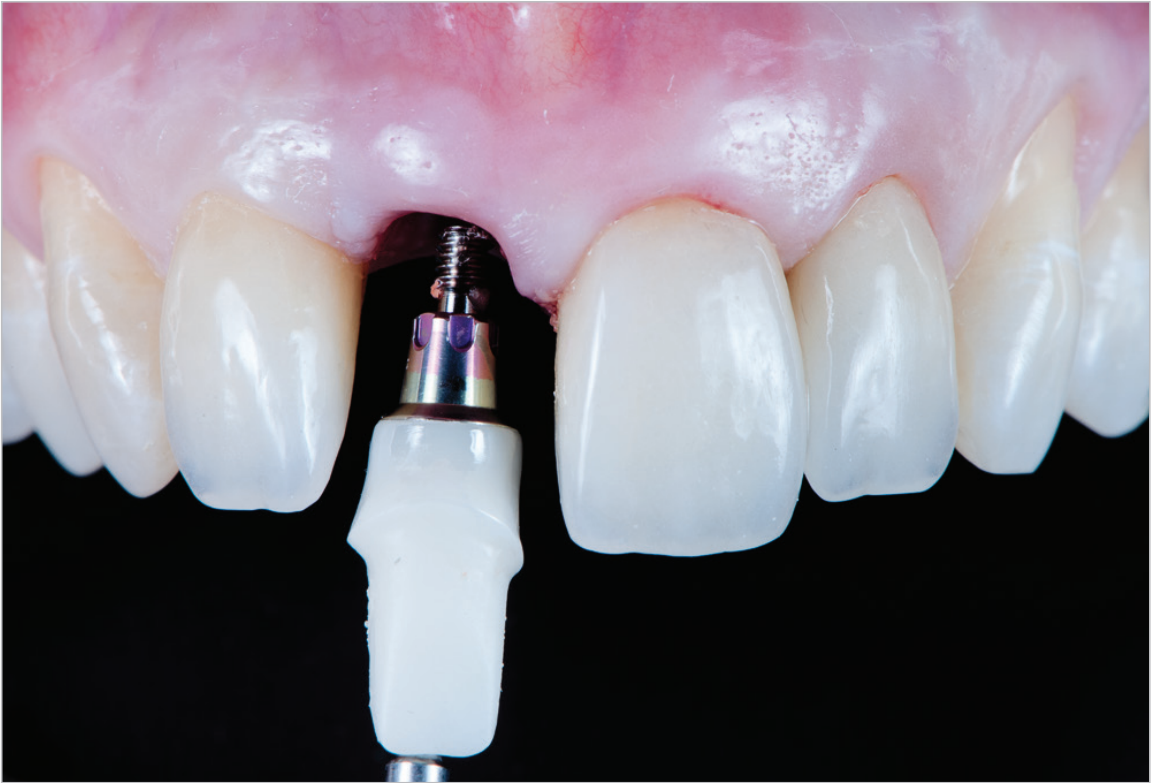

Fig. 12 Zirconia abutment.

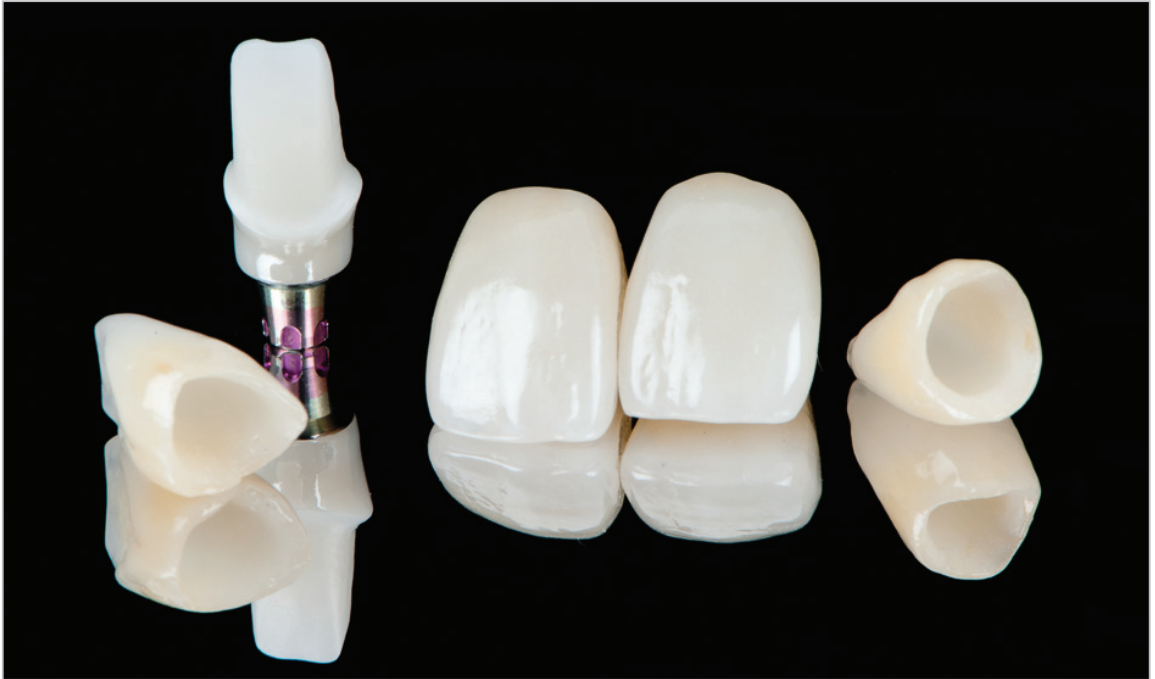

Fig.13 Final restorations.

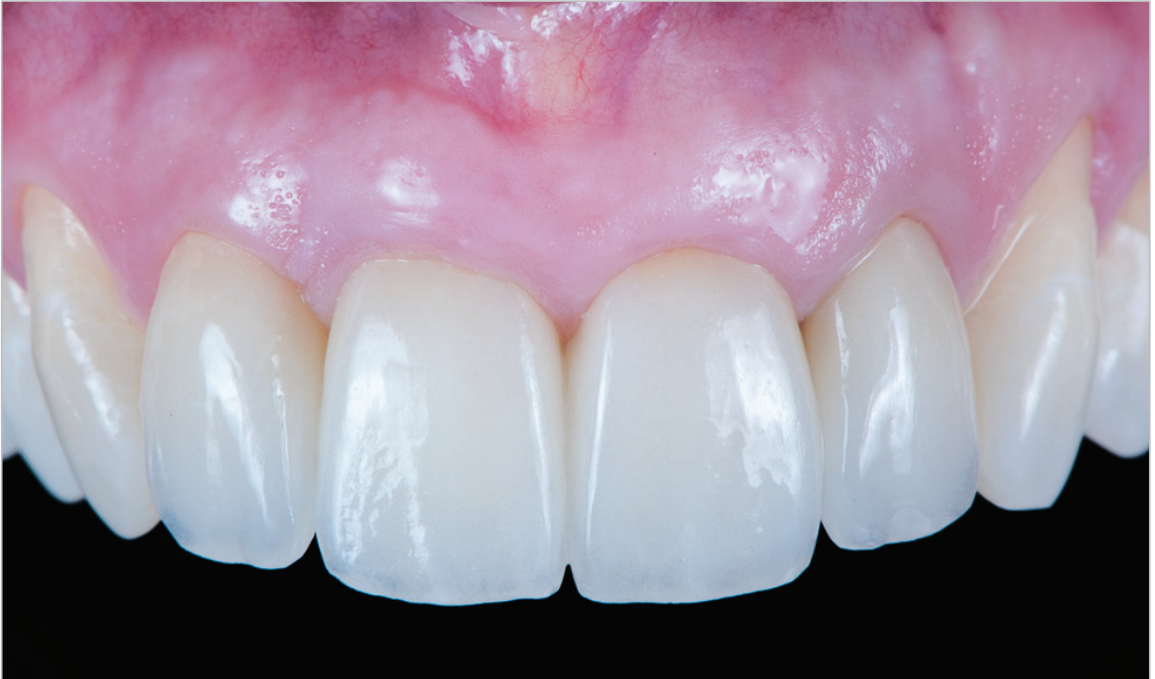

Fig. 14 1-year final result.

## CASE 6.

Surgeon: José Manuel Navarro (Branemark Osseointegration Center, Spain)

Dental Technician: Jordi Tafall, MDT (Zirconstetic)

**Patient:** 38 years old

38 years old patient presents at our clinic with a hopeless UR1. He has had a failed root canal treatment (RTC) and peri-apical surgery as can be seen from the scar in the vestibule area that is presented at the first visit appointment.

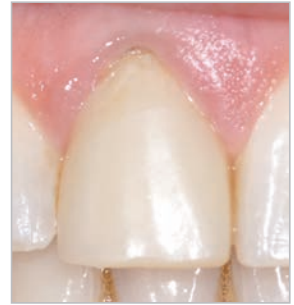
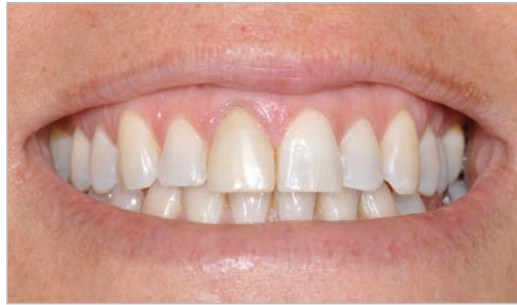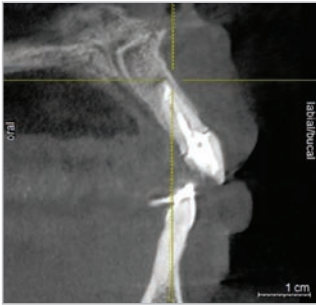


Fig. 1 38 year old patient presents with helpless upper right central incisor.

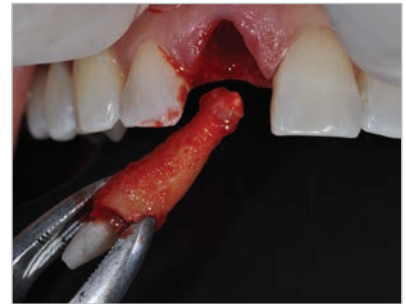
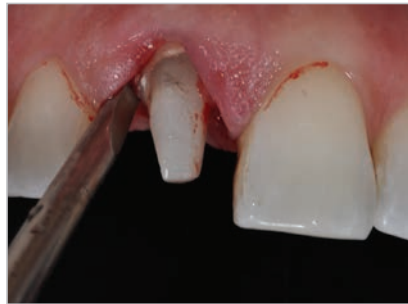
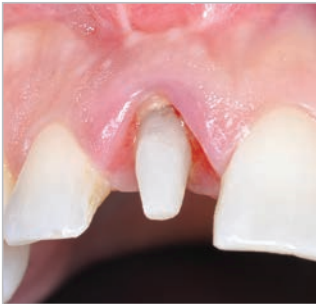Fig. 2 Atraumatic extraction of 11. Note scarring present as result of the peri-apical surgery previously performed and the periodical lesion at root apex

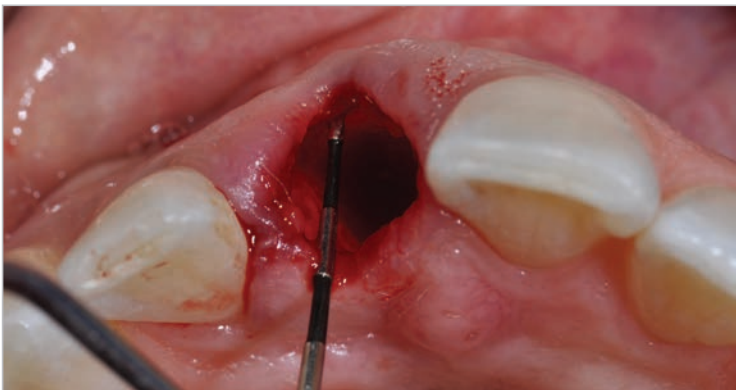


Fig. 3 Favourable buccal bone plate.

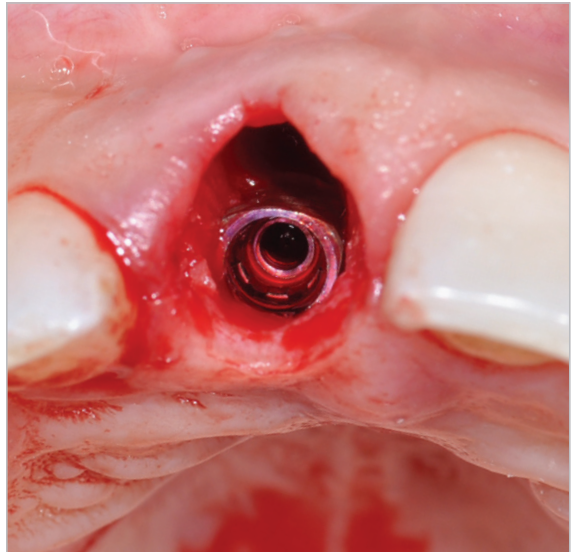
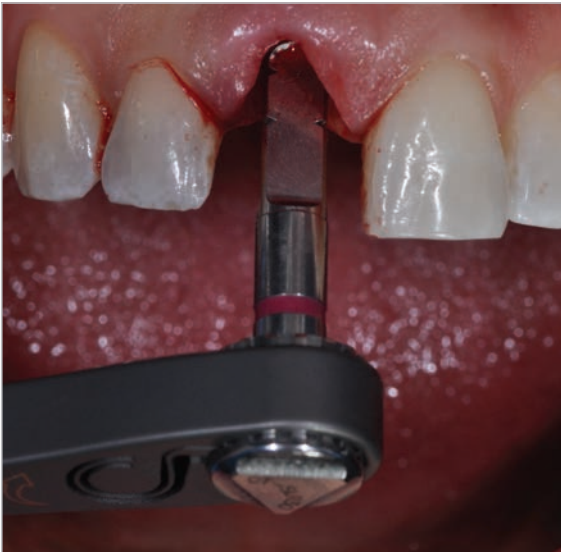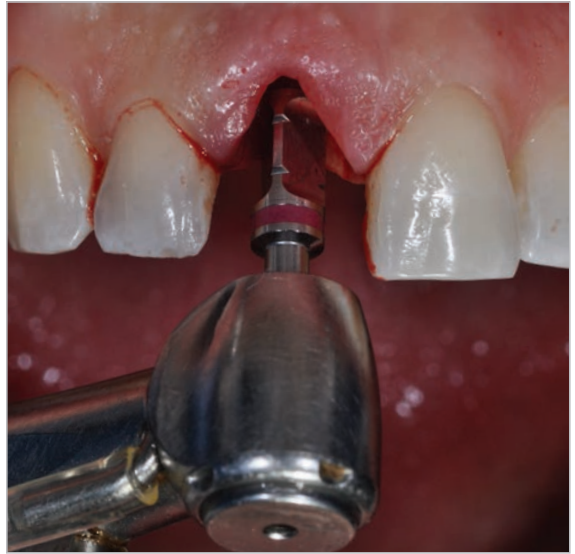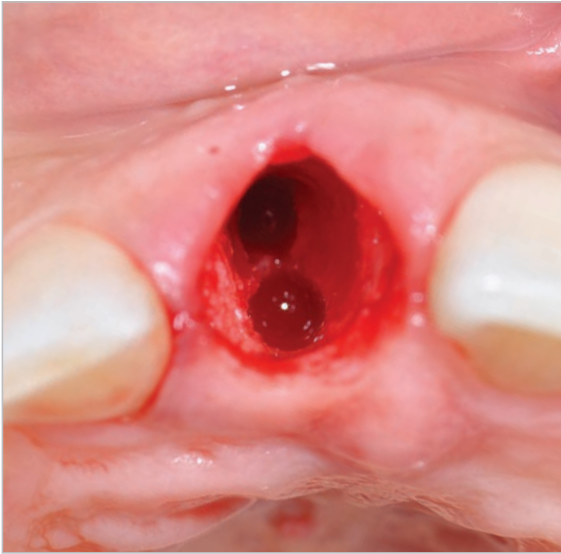


Fig. 4 4.3x16 MIS V3 Implant placement with palatal osteotomy.



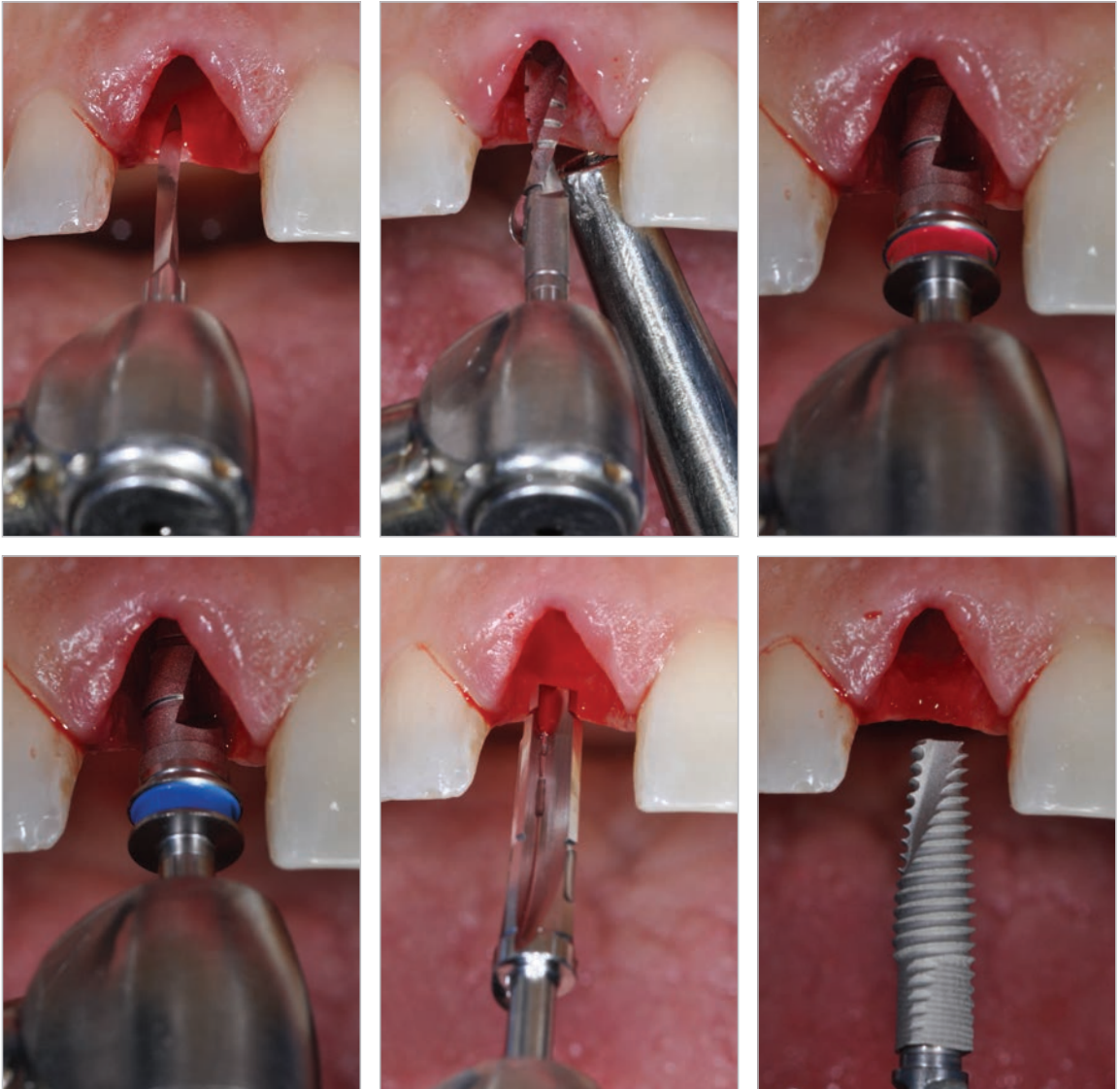


Fig. 5 Detailed drilling sequence and implant placement (MIS V3 4.3x16)



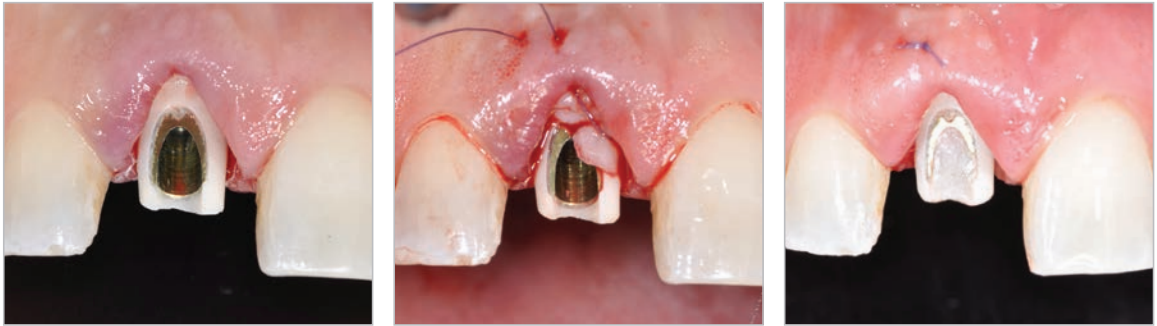

Fig. 6 Placement of the prefabricated screw retained abutment and connective tissue graft.

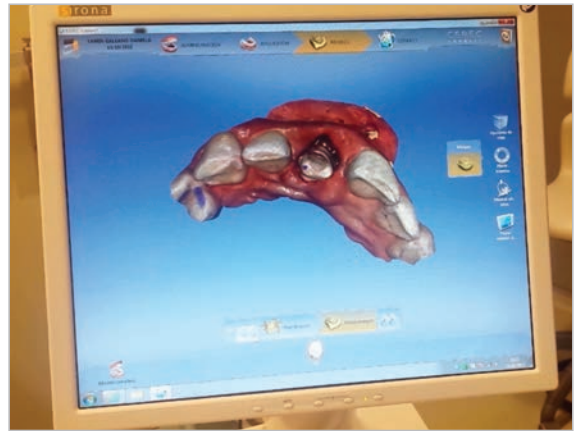
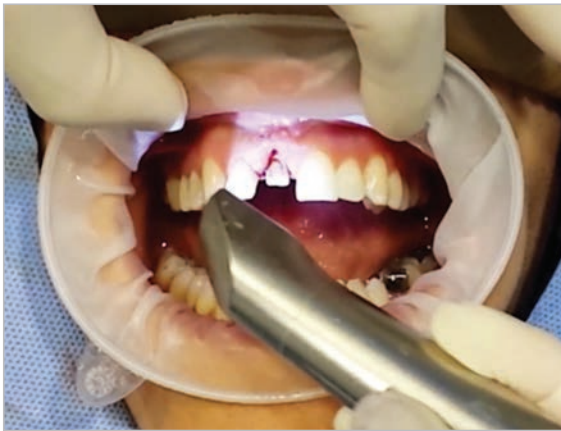
Fig. 7 Digital Impression utilizing CEREC Omnicam.

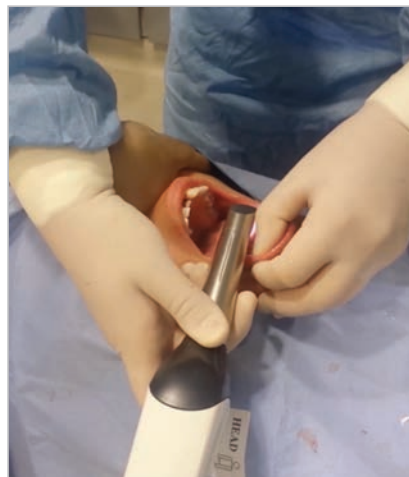
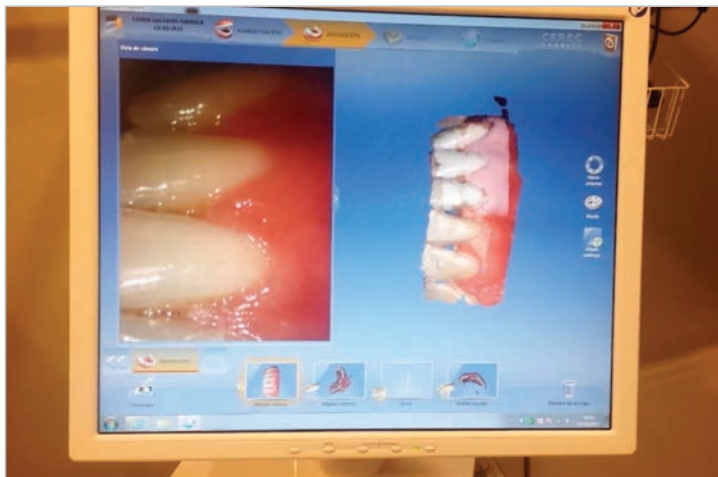


Fig. 8 Digital Impression of opposing arch utilizing CEREC Omnicam.



Fig. 9 Chair-side milling of the provisional crown Vita CAD-Temp.

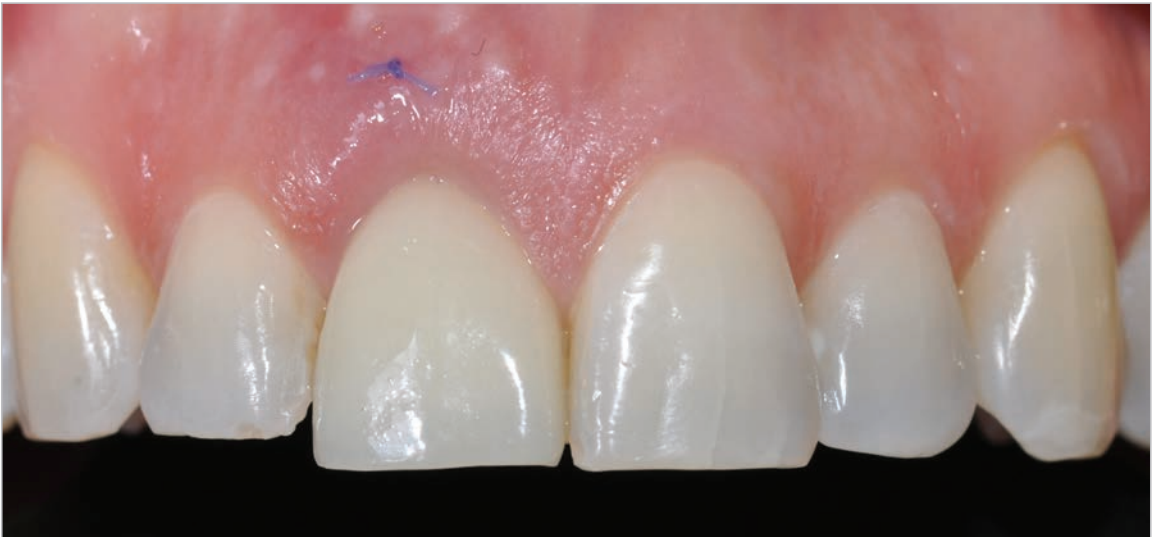
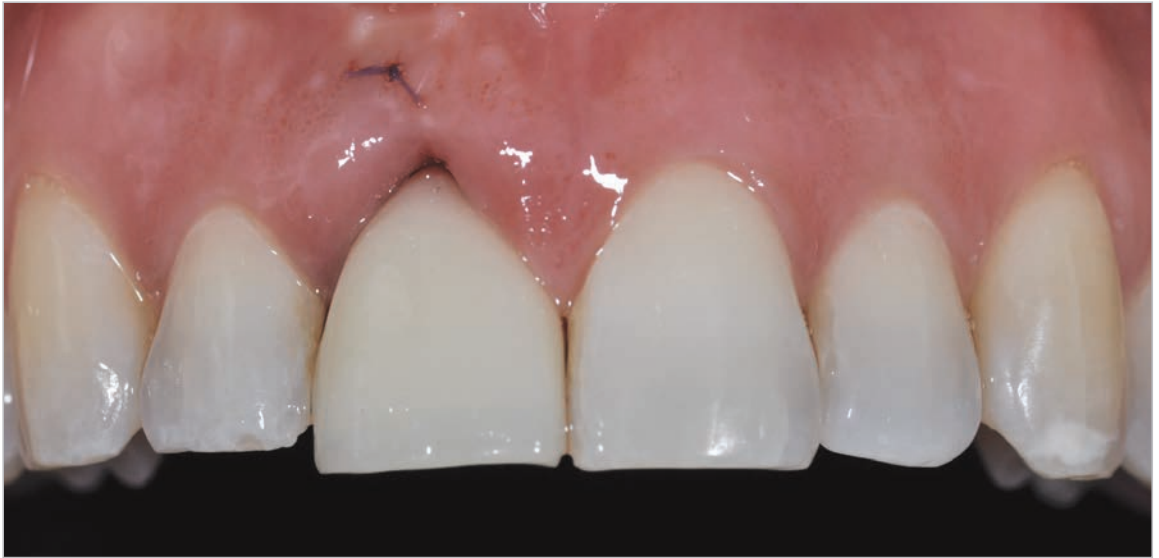
Fig. 10 Provisional crown in place 1/2 hour after the surgical procedure has finished. 1 week Pot-op Review.

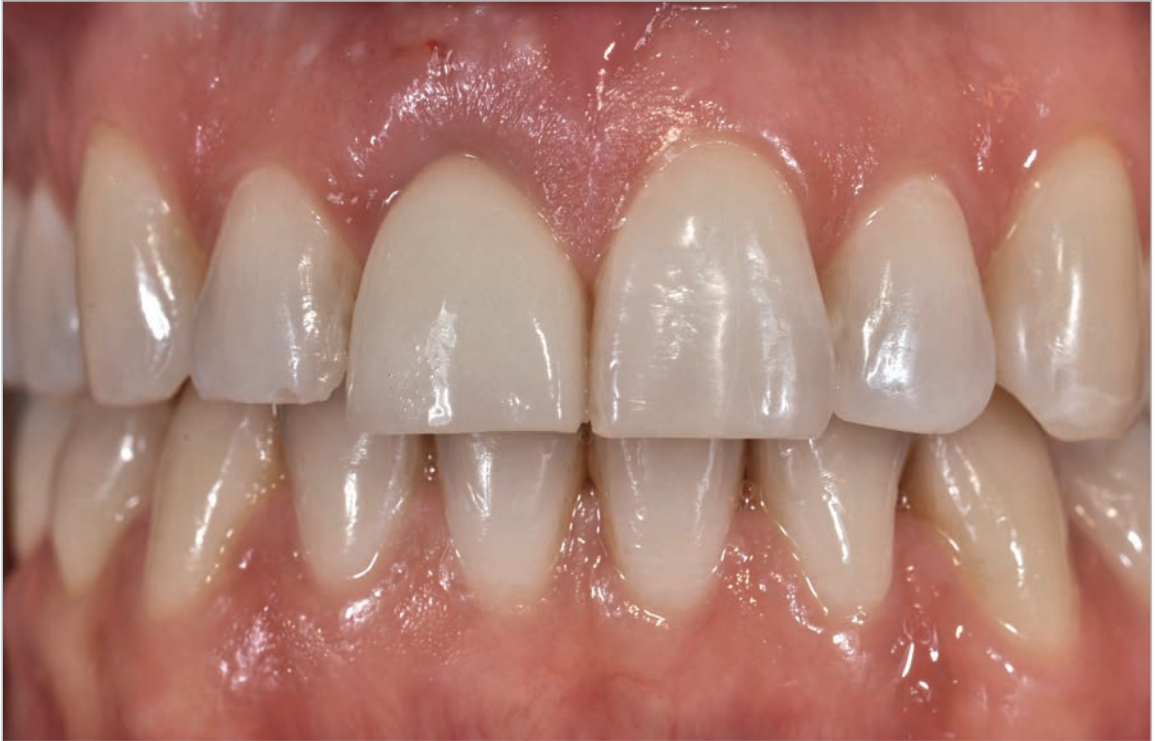

Fig. 11 Suture removal at 1 week.

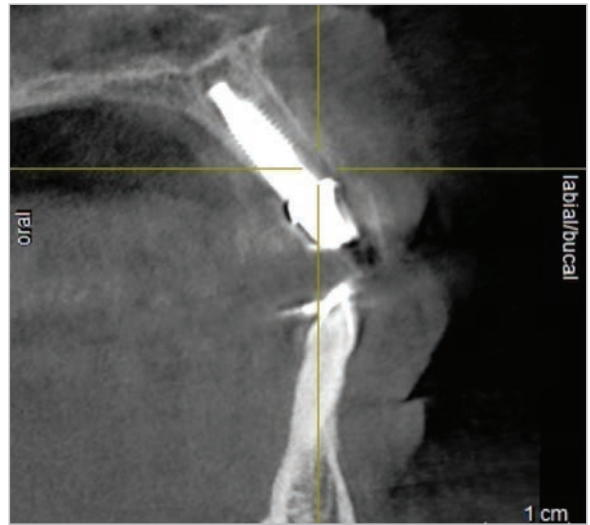
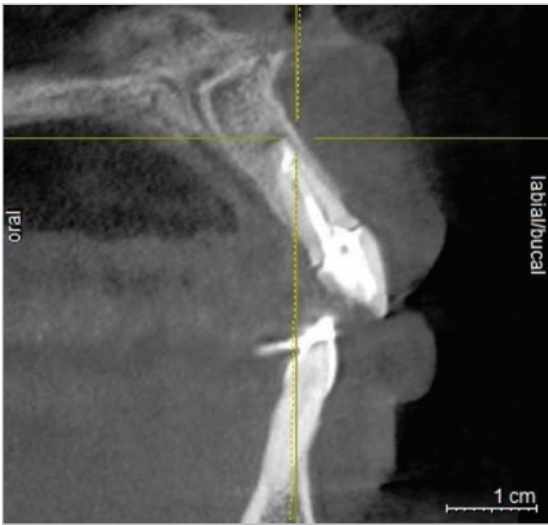


Fig. 12 CBCT showing the situation before the extraction and after the extraction and implant placement. Note presence of buccal bone plate in both images.

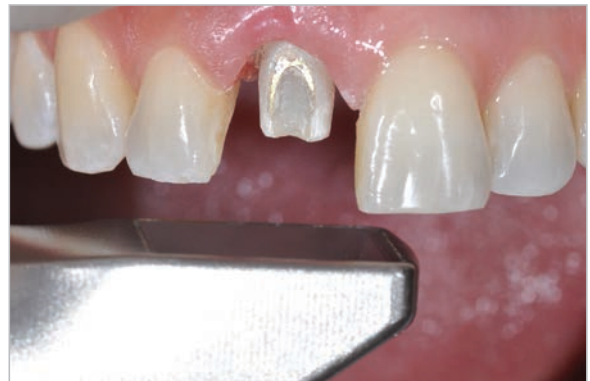
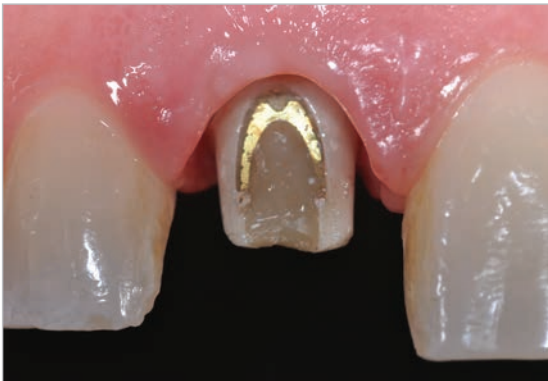
Fig. 13 4 months after the initial surgery impressions are taken for fabrication of the final crown utilizing CEREC Omnicam.



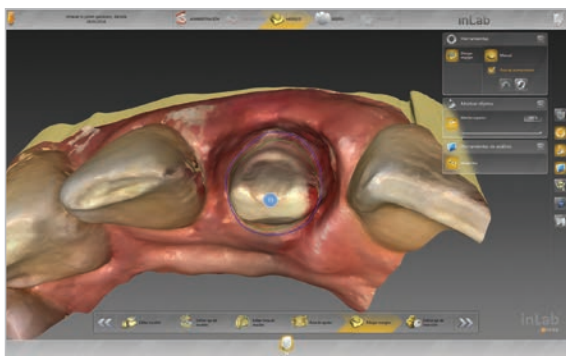


Fig. 14 Design of final Crown in CEREC In Lab 15.

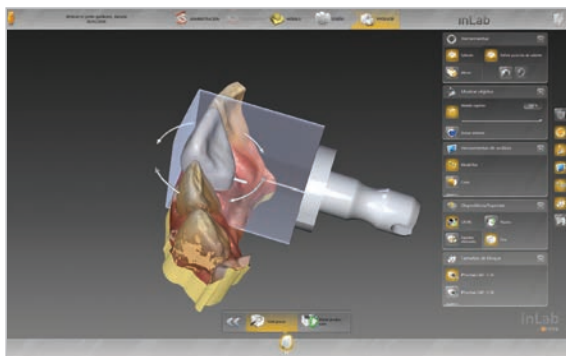
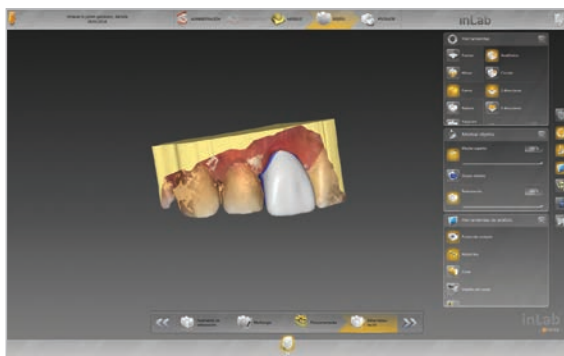


Fig. 15 Milling of the final Lithium Disilicate crown.



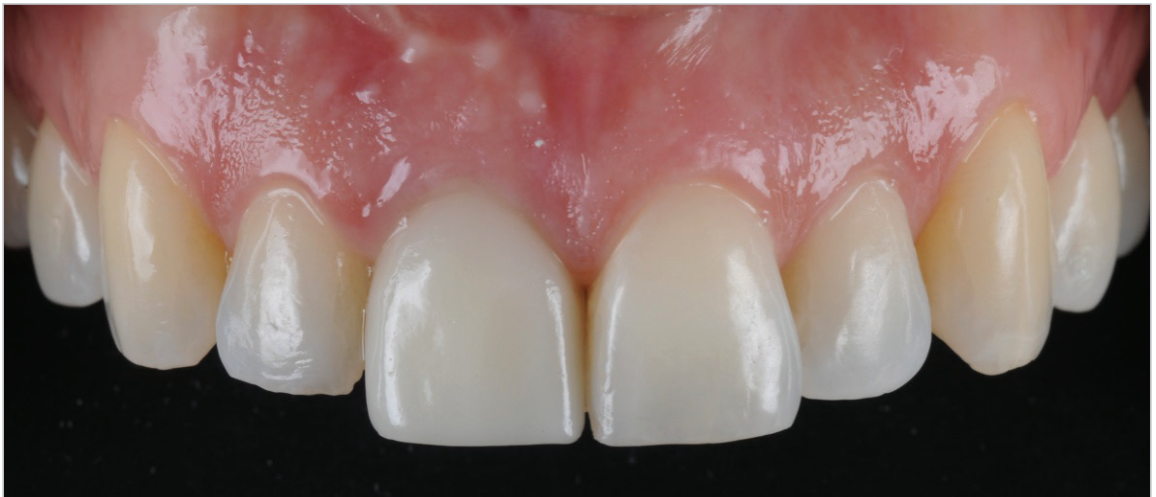
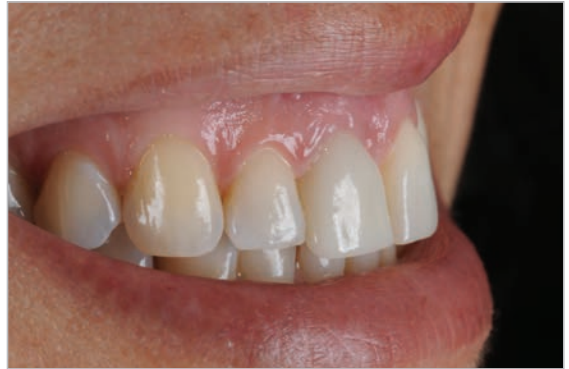
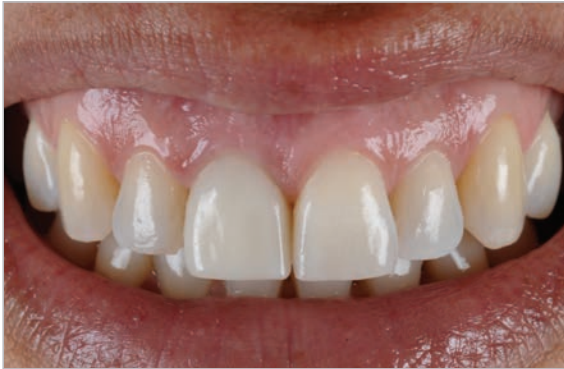Fig. 16 Final photographs





[www.VCONCEPT.com](http://www.VCONCEPT.com)

The MIS Quality System complies with International Quality Standards: ISO 13485:2003 - Quality Management System for Medical Devices, ISO 9001:2008 - Quality Management System and Medical Device Directive 93/42/EEC. MIS products are CE marked.