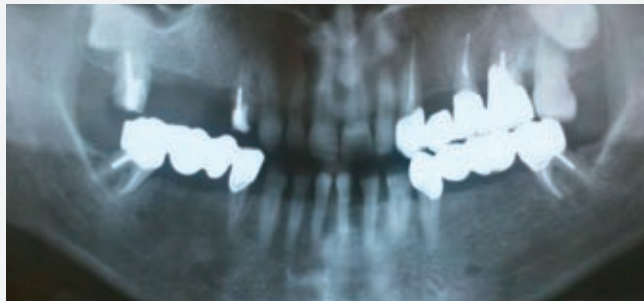

28

News No. 28 October 2011

Bone Regeneration
After Procedure for
Preservation of Alveolar
Ridge with BONDBONE®



mis[®]
Make it Simple

Bone Regeneration After Procedure For Preservation of Alveolar Ridge With BONDBONE®

Dr. Kamen Kotsilkov¹, Dr. Ivaylo Alyakov, DMD

Introduction

Ridge augmentation technics are a matter of choice after tooth extraction in order to prevent the loss of bone as a result of atrophic changes that may occur in time. We can say that for the current widely used alloplastic materials based on betatricalcium phosphate and hidroxyapatite the resorbtion time is 6 - 9 - 12 months¹. This fact needs to be taken in consideration, when placing an implant in an area with guided bone regeneration. The need of using a membrane to immobilize the bone graft and covering it with flap additionally increases the complexity of the procedure. In this case study we are going to demonstrate the capabilities of biphasic calcium sulphate (BONDBONE®) as a bone graft material that provides predictable results and bone regeneration on the 4th month after the usage.

Aim

To present the histopathology result of bone regeneration in a clinical case of conventional implant placing after a procedure for saving the alveolar ridge using BONDBONE®.

Methods And Materials

A 55 years old patient with present bridge constructions - #17_16_15_#14; #23_24_#25_#26; #34_35_36_#37; #44_45_46_#47 placed 5 years ago. The complaints of the patient are connected with recurring periodontic symptoms from tooth #14 (median bridge carrier from the bridge construction - #17_16_15_#14). After the removal of the bridge construction, a 2nd degree of mobility is determined as well as a periapical lesion. After an atraumatic extraction, the socket is filled in with BONDBONE® without having to cover the graft with a membrane. Free gingival autotransplant from the neighboring toothless area is mobilized. The gingiva of the extraction wound is fixed with a modified vertical mattress suture stitch and the gingiva graft is fixated with Ostitches. After 4 months is performed a mucoperiosteal flap with the purpose of placing dental implants on #14, #15 and #16. Bone biopsy is taken with a trephine borer from the places of the future implants. Sample 1 is taken from the spot with BONDBONE® and Sample 2 is from patient's own bone from spot #15. Results of the histopathology- "Fragment of spongios bone with fibrosing of the bone marrow spaces"- Military Medical Academy, department "Patomorfolgy, autopsy and biopsy diagnostic".

Conclusion

The presented clinical case shows that Bond Bone can be used with predictable success in cases where the bone volume of the alveoli ridge needs to be preserved. The advantages of the material are that there is no need to use an immobilizing membrane, as well as the quick hardening of the material in the presence of oral liquids. Having in mind that so far there isn't a similar bone graft material with histomorphology on the 4th month close to natural bone, the product will be subject of additional research.

References

¹ Karl-Erik Kahnberg-Bone Grafting Techniques for Maxillary Implants 2005 Martin Dunitz-Implants and Restorative Dentistry 2001.

¹ Professor assistant at the Parodontology Department " Faculty of Dental Medicine", Medical University Sofia-Bulgaria

Case 1

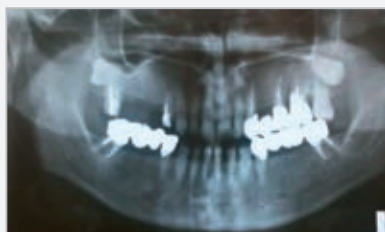

Fig. 1 Ro condition before the extraction of #14 (14.06.2010)

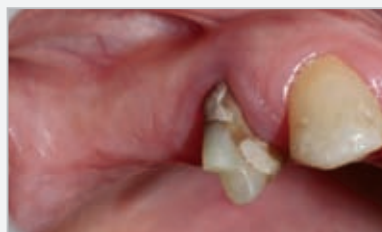

Fig. 2 Clinical condition before the extraction of #14 (16.06.2010)

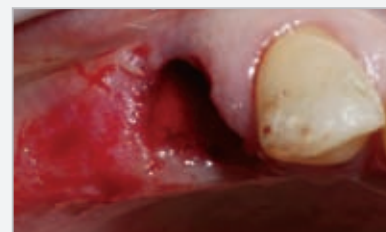

Fig. 3 Extraction of 14 and immobilizing of free gingival autotransplant

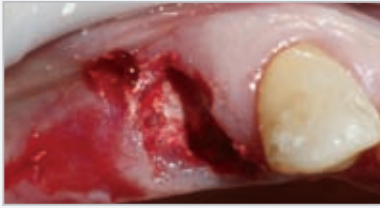


Fig. 4 After an atraumatic extraction the socket is filled with BONDBONE®

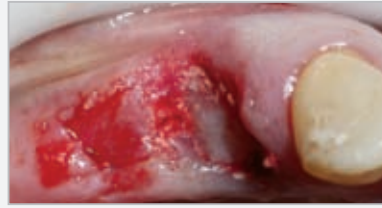

Fig. 5 Placement of the free gingival transplant of the toothless area

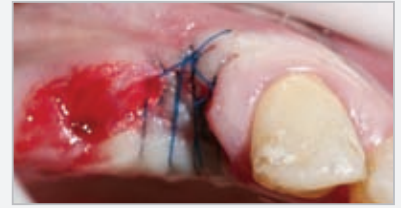

Fig. 6 Ligation of the extraction wound and a gingival transplant with O-stiches

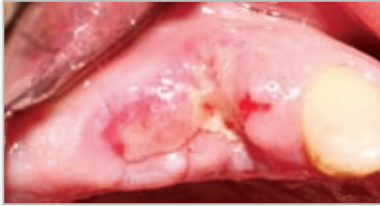


Fig. 7 Removing of the thread (25.06.2010)

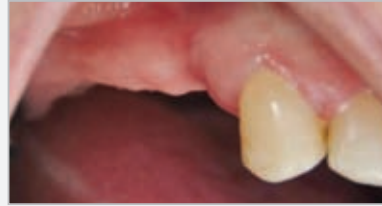

Fig. 8 Clinical view before placement the dental implants (16.10.2010) 4 months later

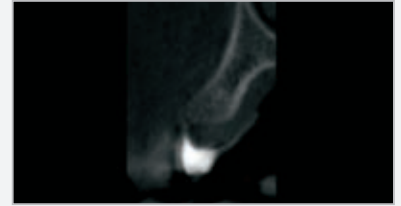


Fig. 9 Ro image of (CBCT) of the area with procedure of the volume preservation of the alveolar bridge with BONDBONE®

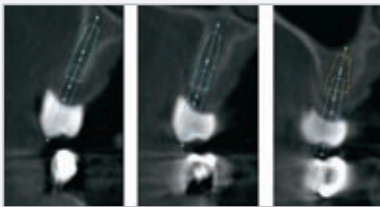


Fig. 10 Planning of the implant positioning for the preparation of surgical model

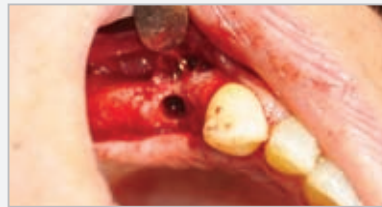

Fig. 11 Bone biopsy with trephine borer from the area of the future implants #14, #15 and #16

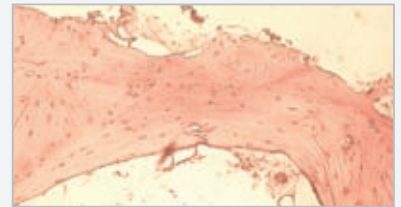


Fig. 12 Sample 1- histology

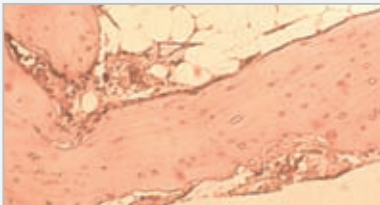

Fig. 13 Sample 2- control sample

Case 2

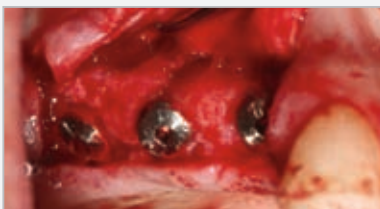

Fig. 1

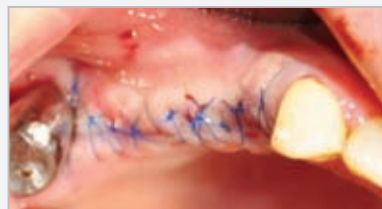

Fig. 2 Reposition and fixation of the mucoperiosteal flap with modified vertical mattress suture and O-stiches.

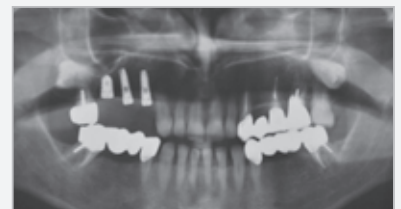

Fig. 3 Ro condition after the surgical intervention

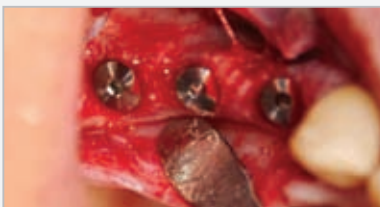

Fig. 4 The dental implants

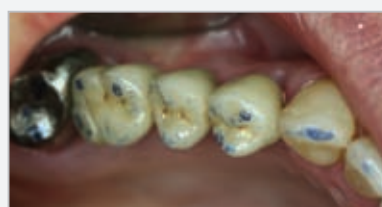

Fig. 5



Fig. 6

MIS's Quality System complies with international quality control standards: ISO 13485:2003 - Quality Management System for Medical Devices, ISO 9001: 2008 - Quality Management System and CE Directive for Medical Devices 93/42/EEC. MIS's products are cleared for marketing in the USA and CE approved.

© MIS Corporation. All rights Reserved

The logo for MIS (MIS Implants Technologies) features the lowercase letters 'mis' in a white, sans-serif font. The letter 'i' is positioned above the 's', and a registered trademark symbol (®) is located to the right of the 's'. The entire logo is set against a solid purple background.

MIS Implants Technologies Ltd.
www.mis-implants.com